Odontojenik Olmayan Benign ve Malign kemik Tümörleri

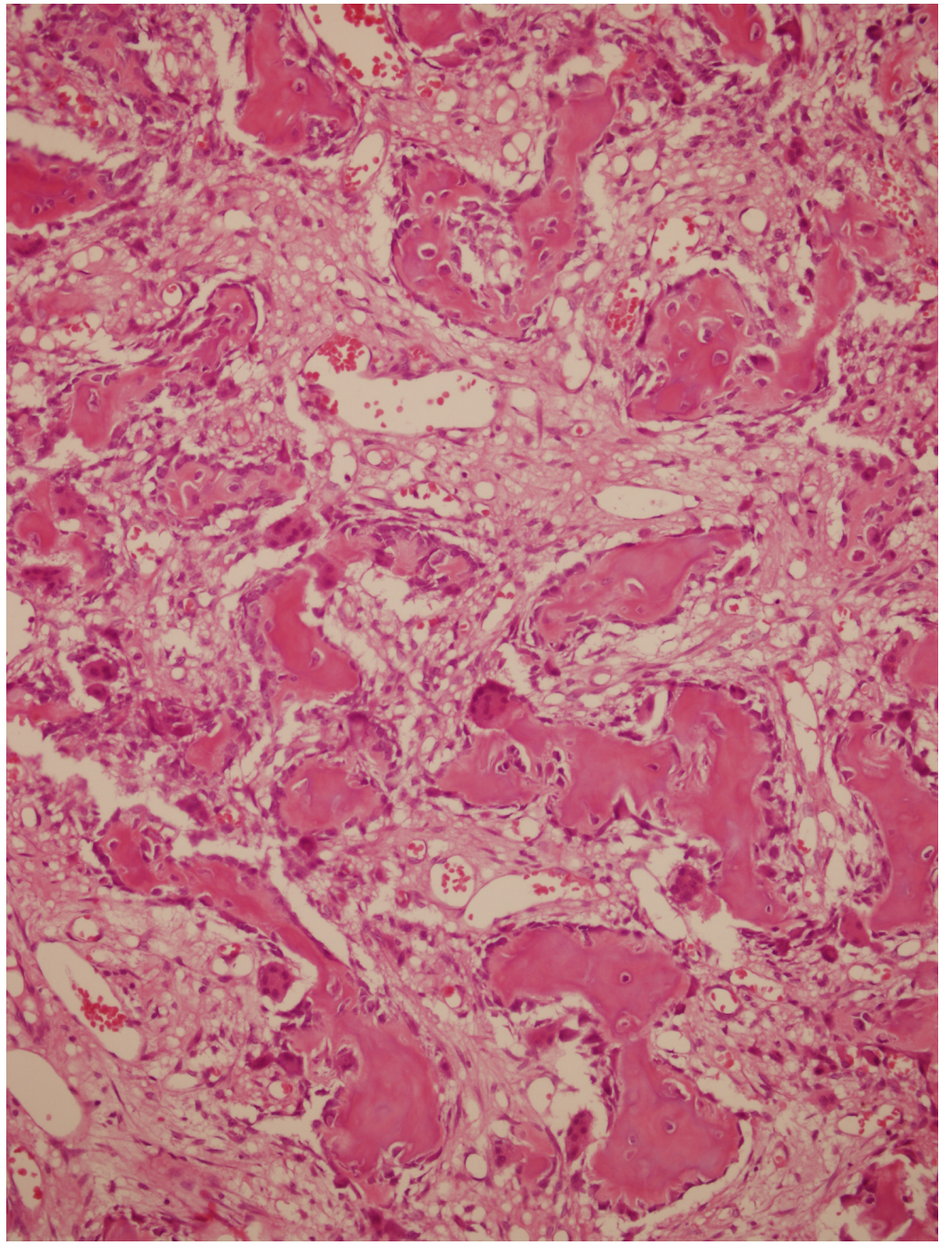

Dr. Y. Sancar Barış
OMÜ Tıp Fakültesi Tıbbi Patoloji ABD

Hedefler

- Kemik patolojilerinin değerlendirilmesindeki ilkeleri açıklayabilmeli
- Oral bölgenin benign kemik tümörlerini söyleyebilmeli
- Oral bölgenin malign kemik tümörlerini söyleyebilmeli
- En sık kemik metastazı yapan tümörleri sayabilmeli

Kemik patolojisi

- Yaş
- Lokalizasyon
- Radyolojik bulgular
- Klinik öykü
- Tek başına patoloji hataya açık
- Mümkünse mültidisipliner kemik konseyinde tartışılmalı

Kemik patolojisi

- Malign tümörler hematojen metastaz yapar: AC; TNM yerine lokal yayılım ve uzak metastaz varlığı önemli

- Doğru tanı doğru tedavi önemli:

  - Küretaj + greftleme: benign lezyonların çoğu

  - Küretaj + lokal ek tedavi: lokal agressif lezyonlar, örn. dev hücreli tm

  - Neoadjuvan KT + cerrahi: OS, Ewing

  - KT / RT: Lenfoma, miyeloma

  - Sadece cerrahi: Düşük dereceli OS, kondrosarkom

Kemik tümörleri

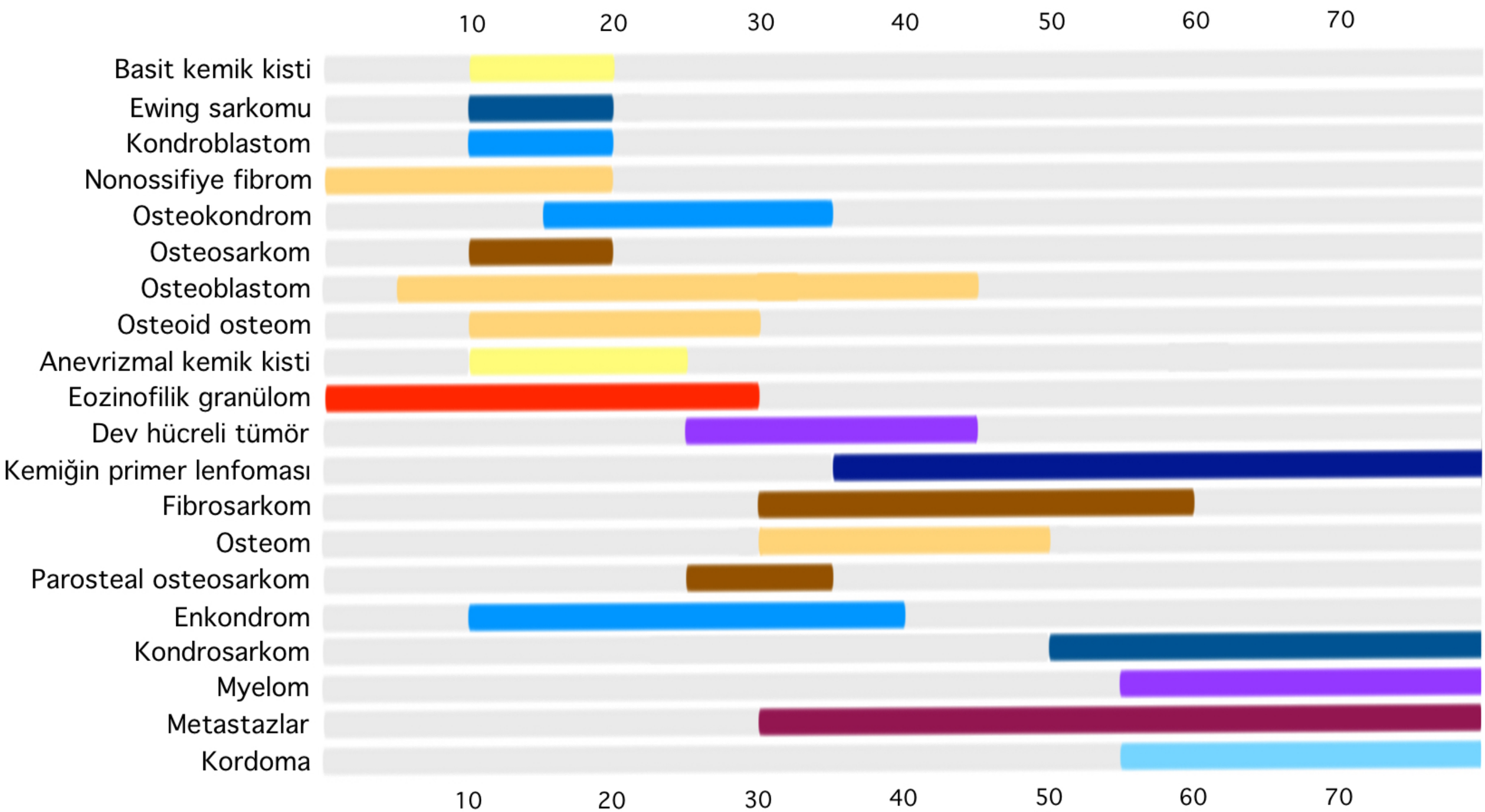

Kemik tümörleri

Benign

- Ossifiyan fibrom
- Fibröz displazi
- Osteoblastom
- Osteoid osteom
- Santral dev hücreli granülom
- Dev hücreli tümör
- Anevrizmal kemik kisti
- Hemanjiyoma
- Langerhans hücreli tümör
- Osteom
- Torus ve ekzostoz

Malign

- Osteosarkom
- Kondrosarkom
- Ewing sarkomu
- Plazma hücreli neoplaziler
- Metastazlar

Ossifiyan fibrom

- Sementleşen fibrom
- Yavaş - ekspansif
- Çene - diş bölgesi
- En sık mandibula premoler-moler bölge
- 3-4. dekatlar ♀>♂
- Fibröz stroma içinde trabeküler / sferik / sementoid kemik matriksi

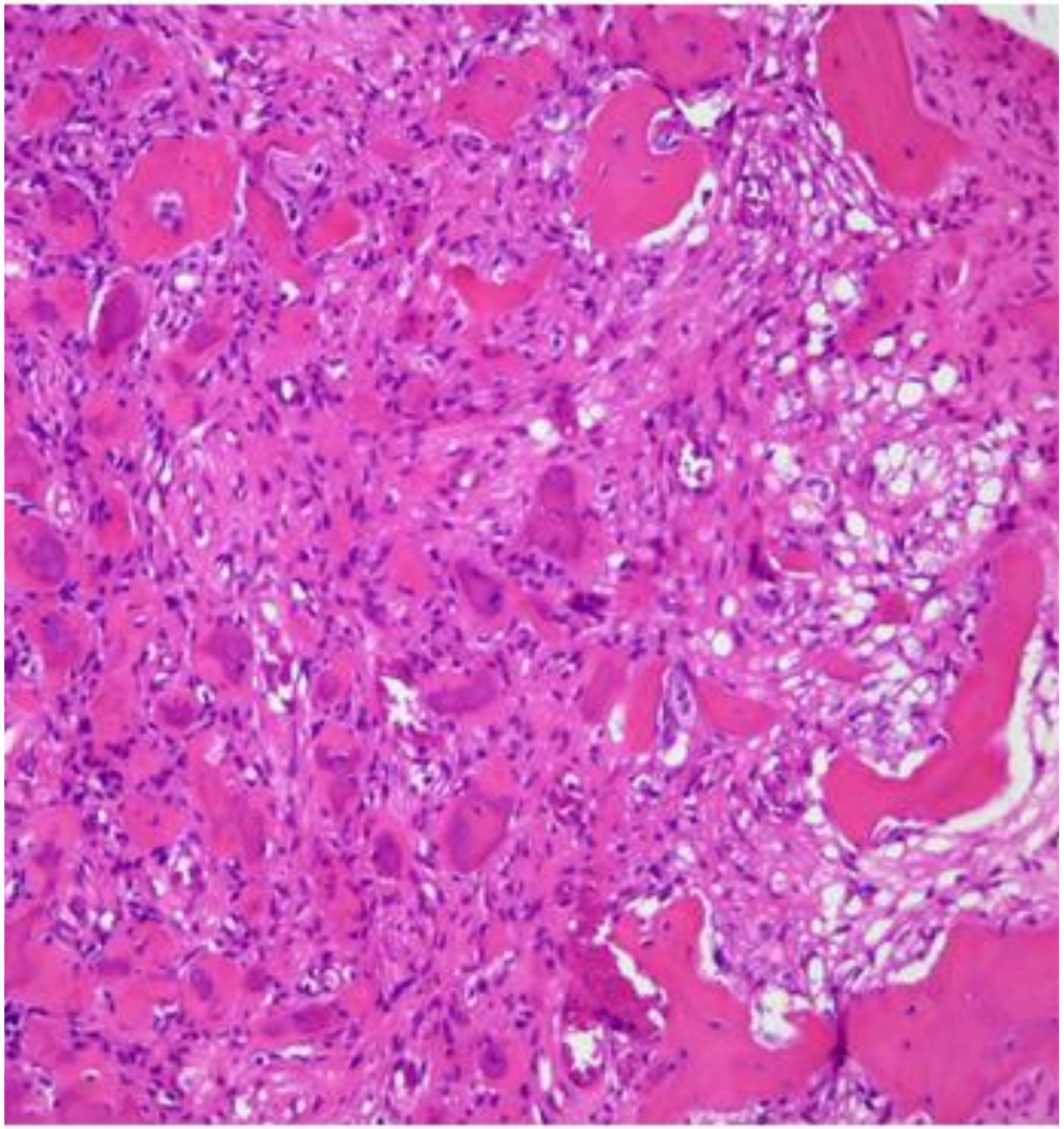

Fibröz displazi

- Osseöz metaplazi yapan fibröz doku
- Yavaş ekspansiyon, deformite
- İlk bulgular 1 ve 2. dekad
- ♀= ♂
- Monostotik /poliostotik
- Kraniyofasiyal fibröz displazi

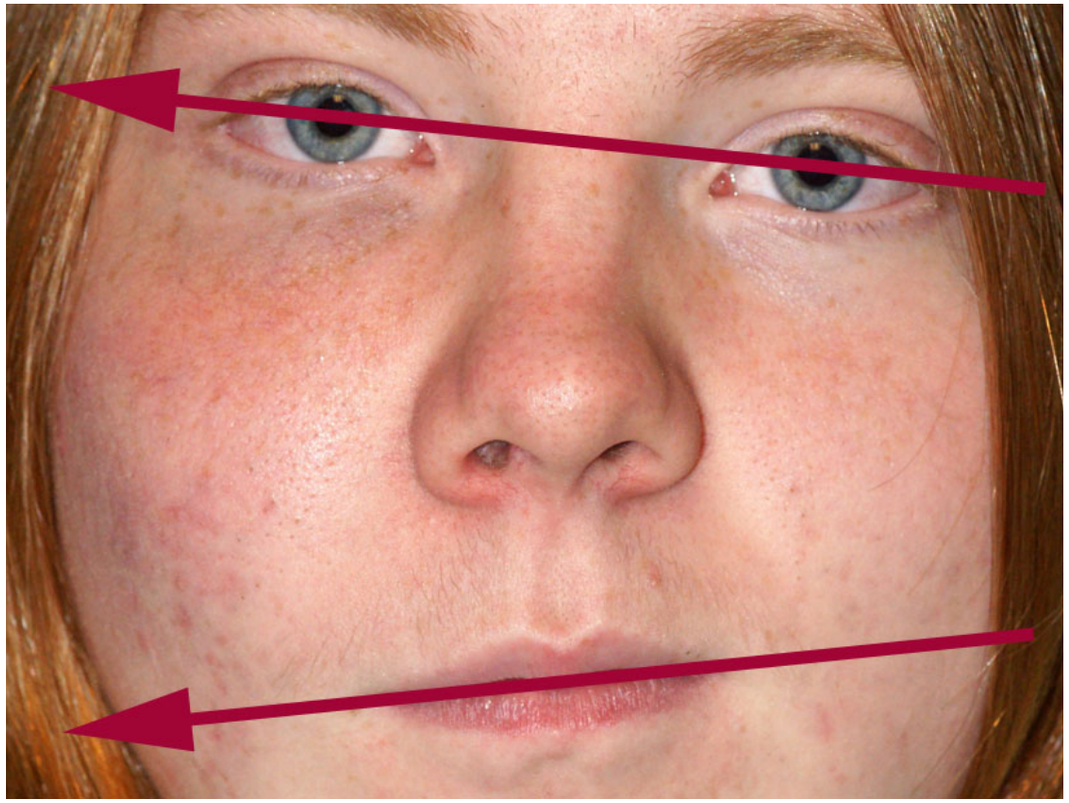

T: 20mm
80
70
60
50
40
30
20
10

Fibröz displazi

- En sık maksilla
- Fibröz doku içinde ince düzensiz trabeküller: Çin harfleri
- Osteoblast yok, doğrudan metaplastik
- Malignensi gelişebilir

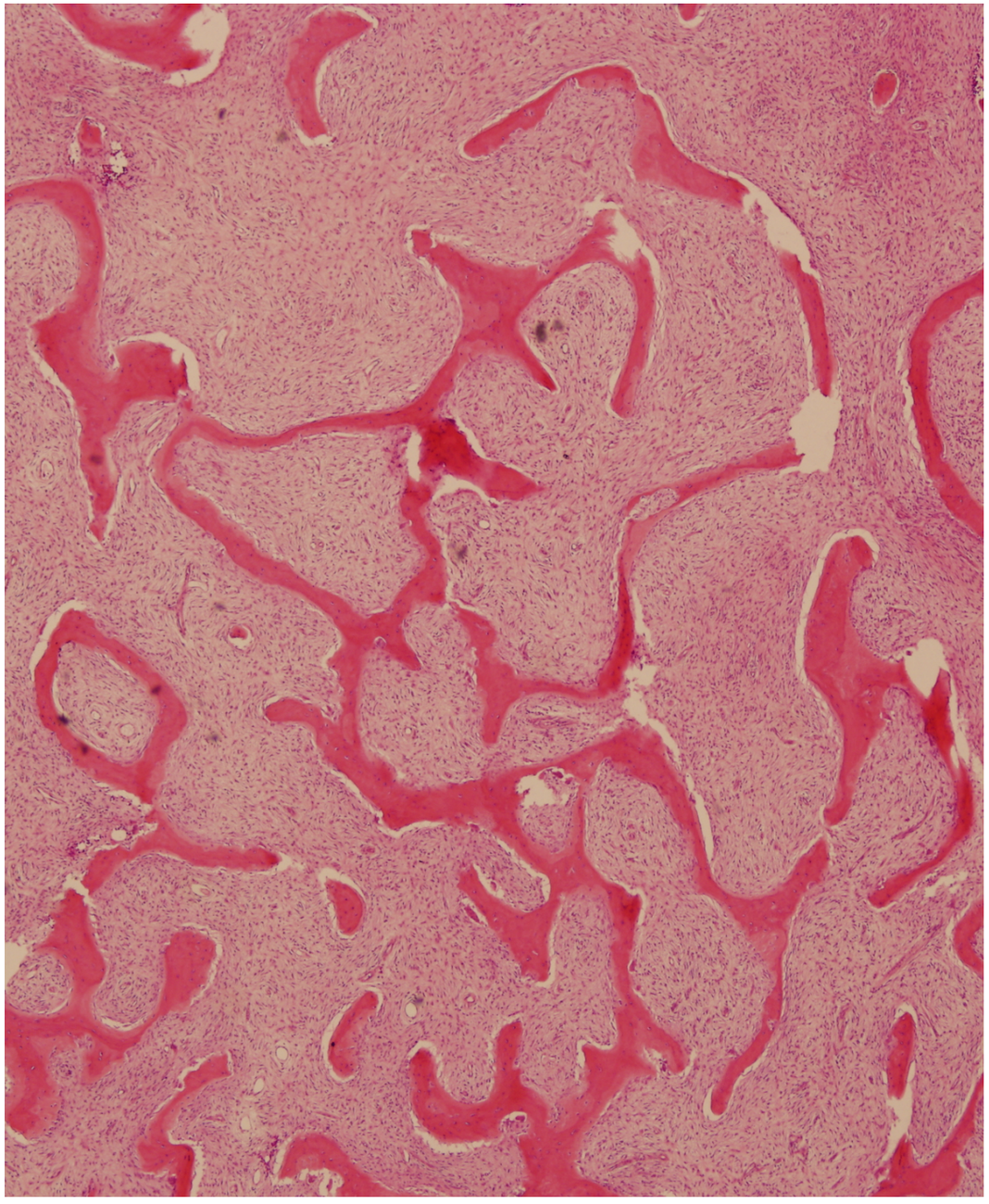

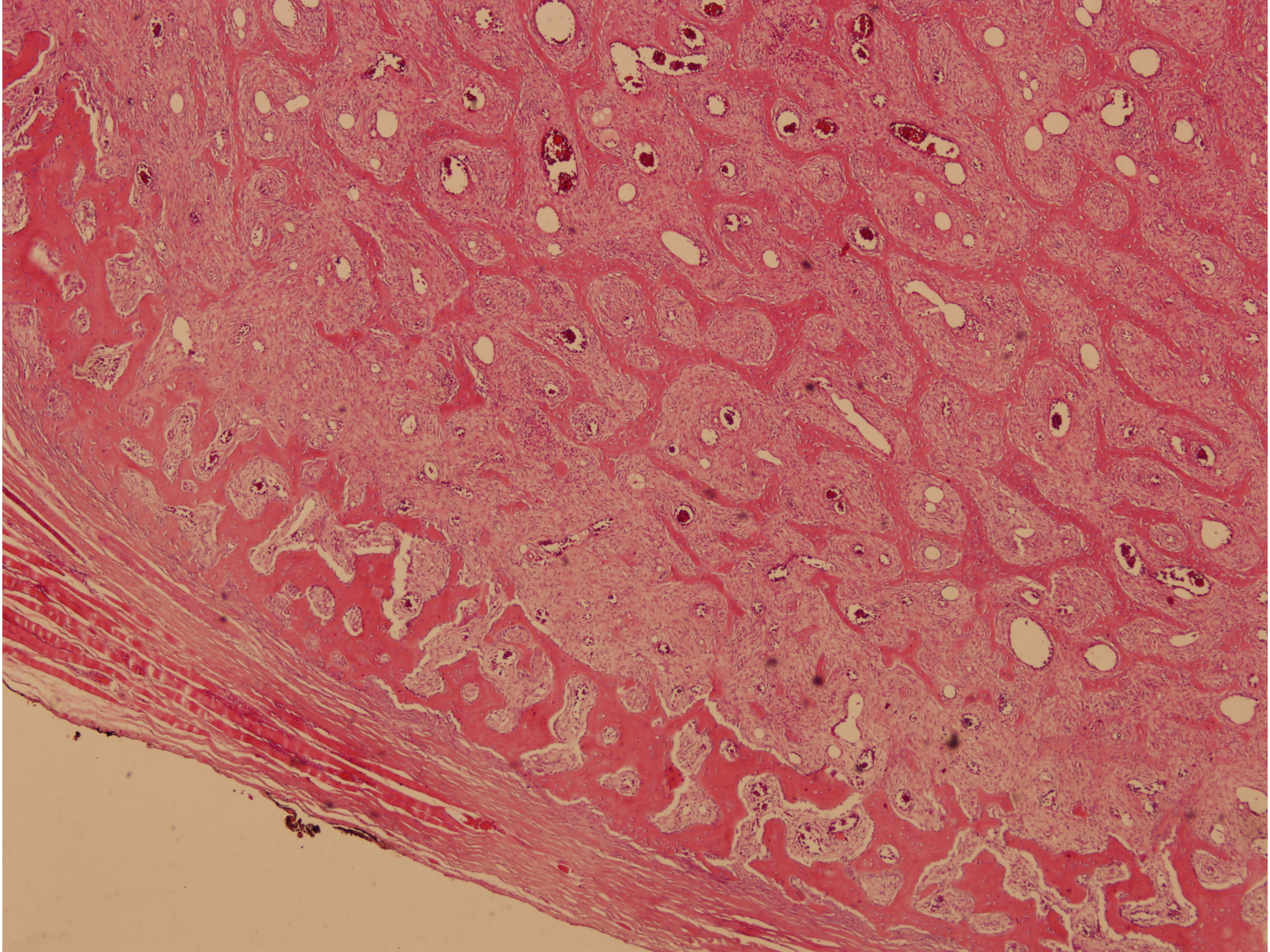

Osteoblastom

- Nadir, en sık mandibula
- Arka diş bölgesi
- Ağrı
- Litik stklerotik, >1 cm
- Aktif osteoblastlar, kemik yapımı, dev hücreler
- Normal kemikle devam eder

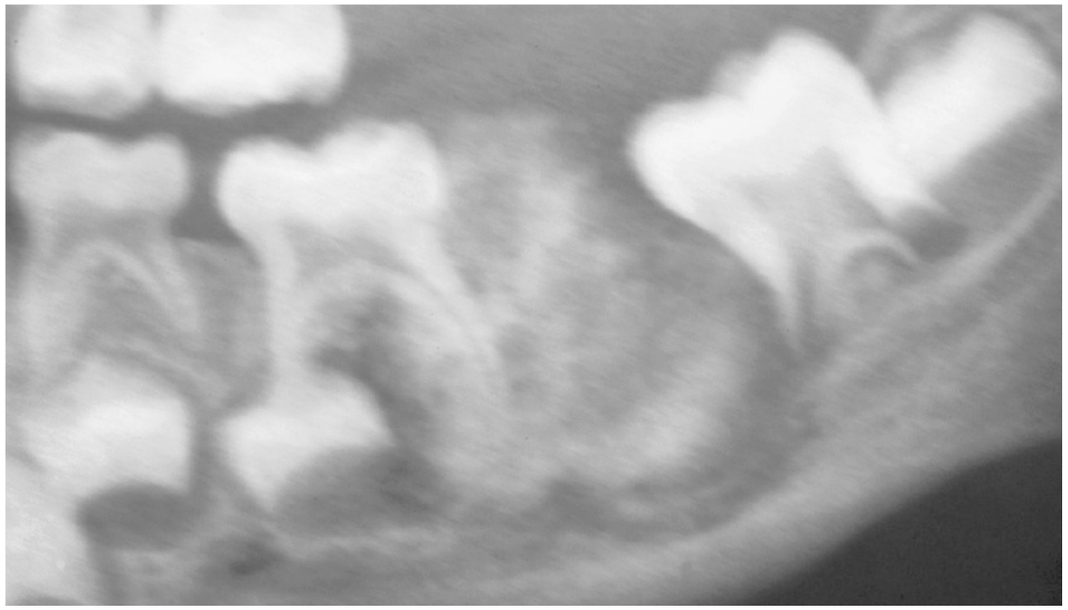

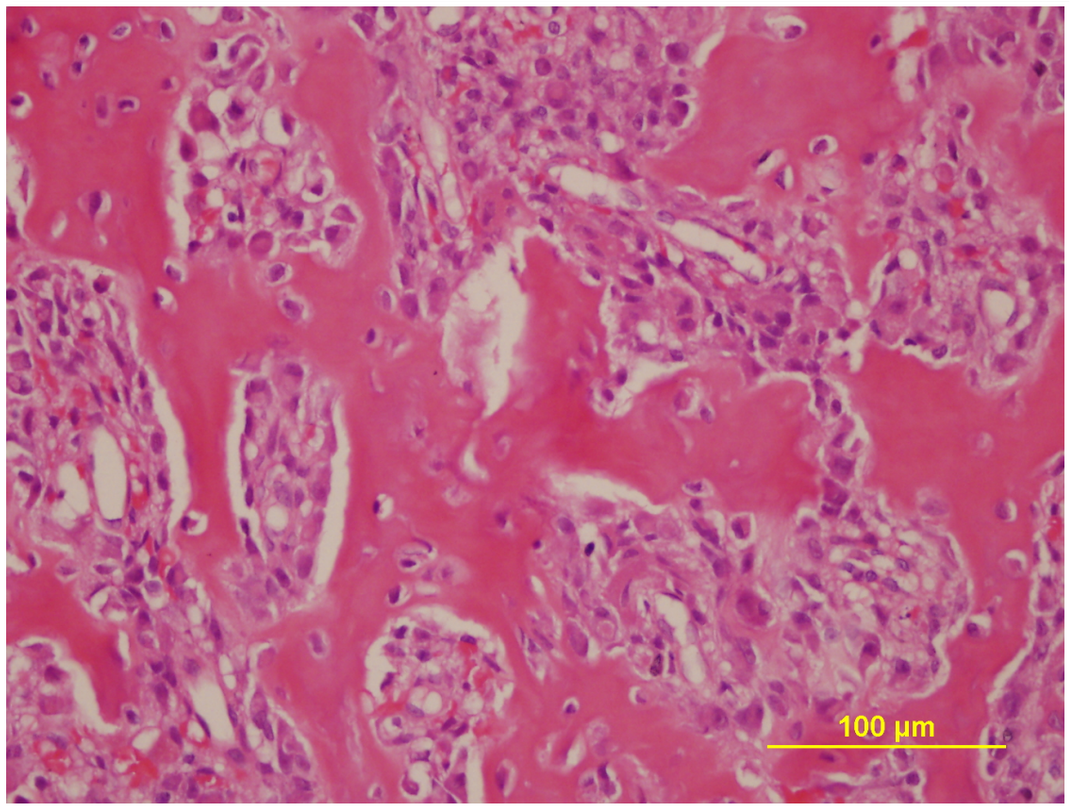

Osteoid osteoma

- Nadir, maksilla, mandibula
- Gece ağrısı, aspirine yanıt verir
- <2 cm
- Radyoloji tipik skleroz ve nidus
- Mikroskopi osteoblastom gibi

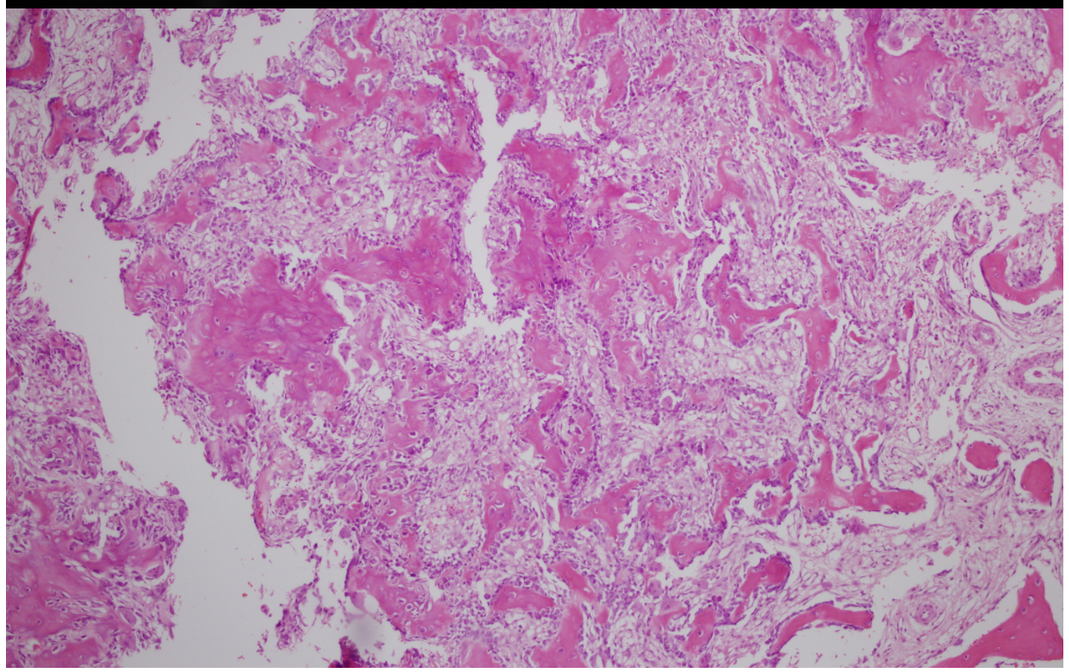

Santral dev hücreli granülom

- Genç erişkin ve çocuklarda
- f♀= 2 x f♂
- En sık mandibula, sonra maksilla
- Genellikle önde, molar dişlerin anteriorunda
- Ağrısız şişlik
- İğsi hücreler, bol damar, kanama alanlarında dev hücreler

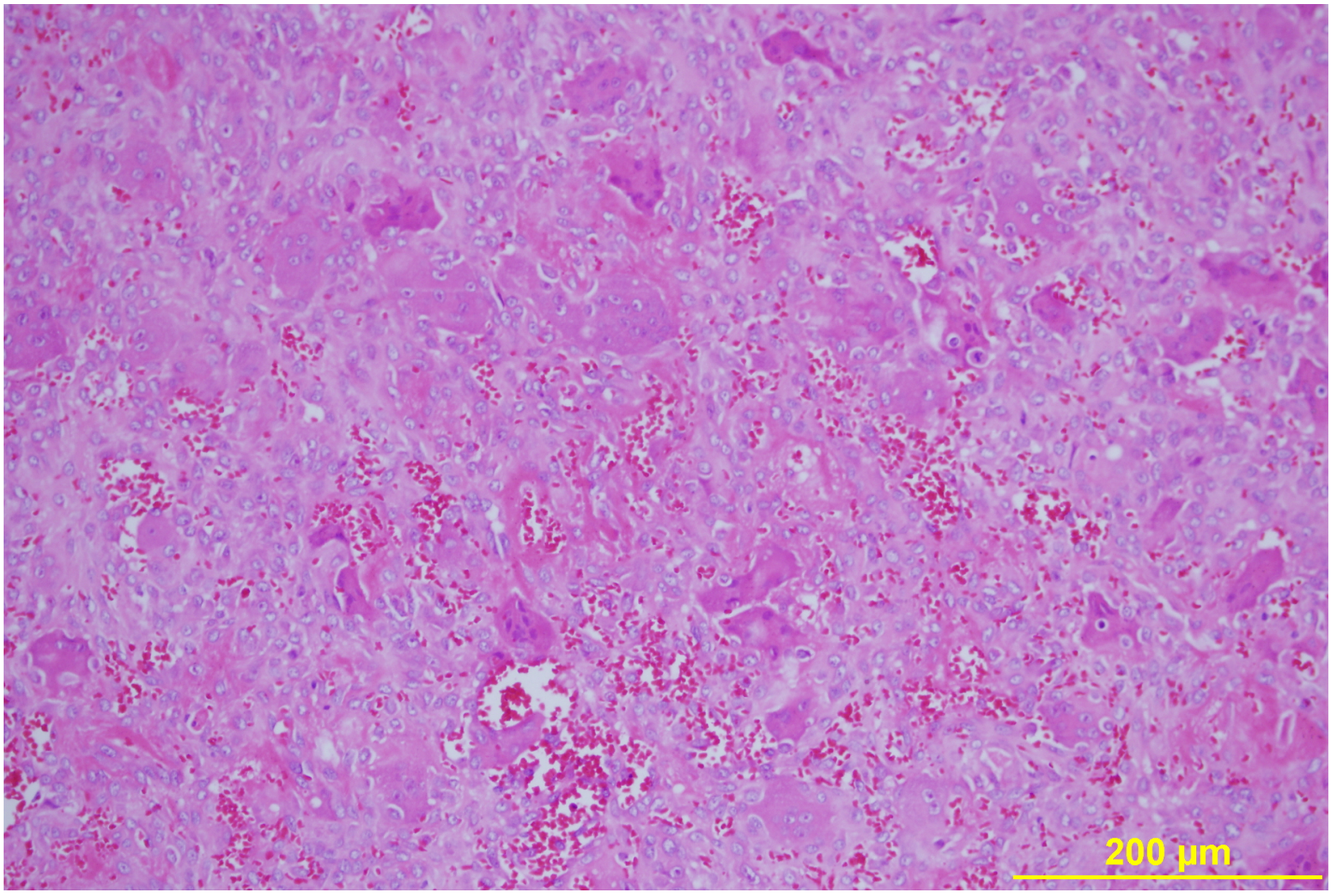
200 µm

Dev hücreli tümör

- 3. ve 4. dekadlar
- ♀>♂
- Kraniyofasiyal en sık çene kemikleri, her kemikte olabilir
- Litik ekspansil kitle
- Mononükleer hücreler, çok çekirdekli çok sayıda dev hücre

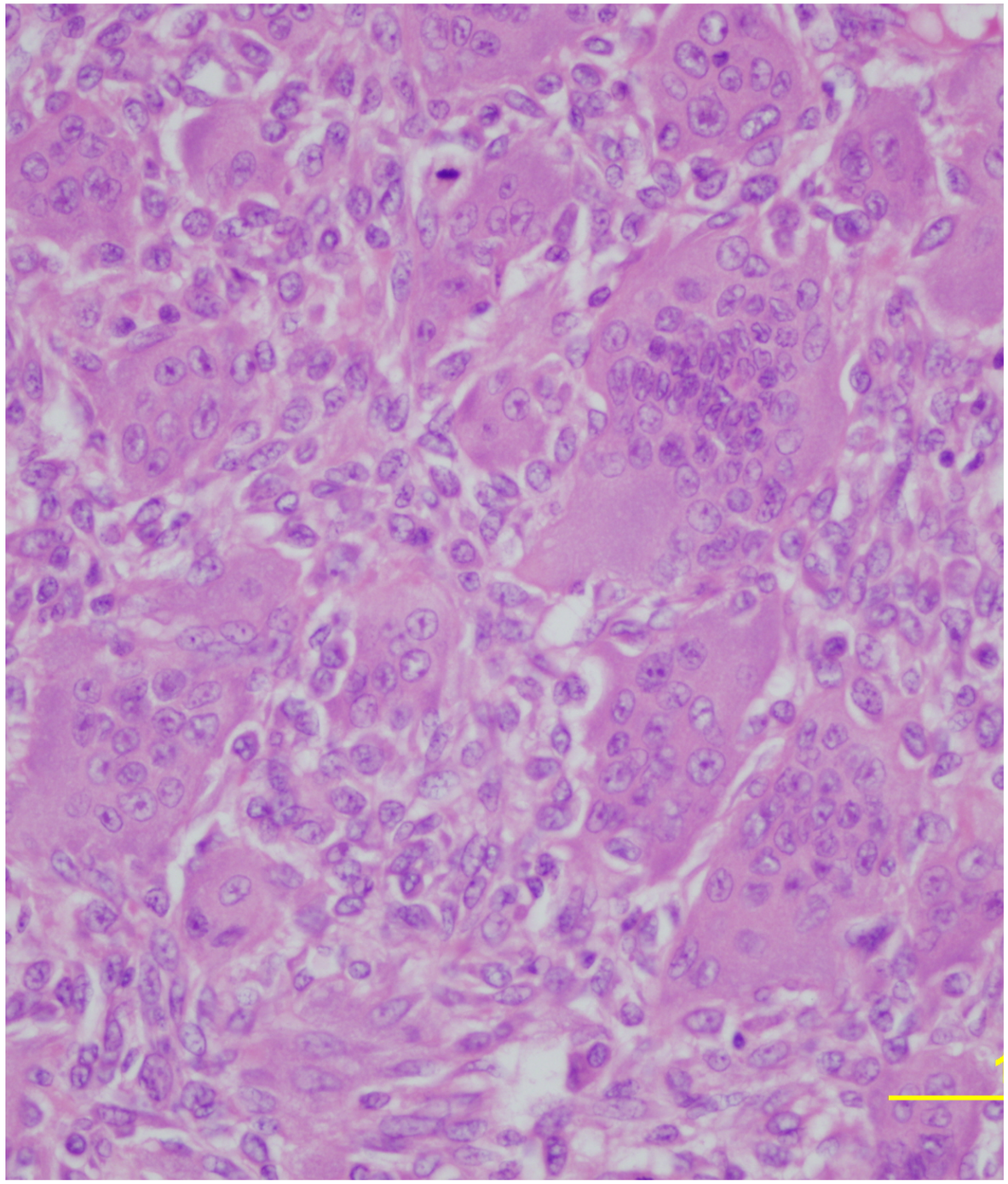

Anevrizmal kemik kisti

- Genç erişkinler, genelde <30y
- Primer ya da sekonder
- Fibröz displazi, osteoblastom, dev hücreli tümör, osteosarkoma sekonder olabilir
- ♀ > ♂
- En sık mandibüla, sonra maksilla
- Kan emmiş sünger gibi içi kan dolu boşluklar, çevresinde reperatif doku ve reaktif kemik

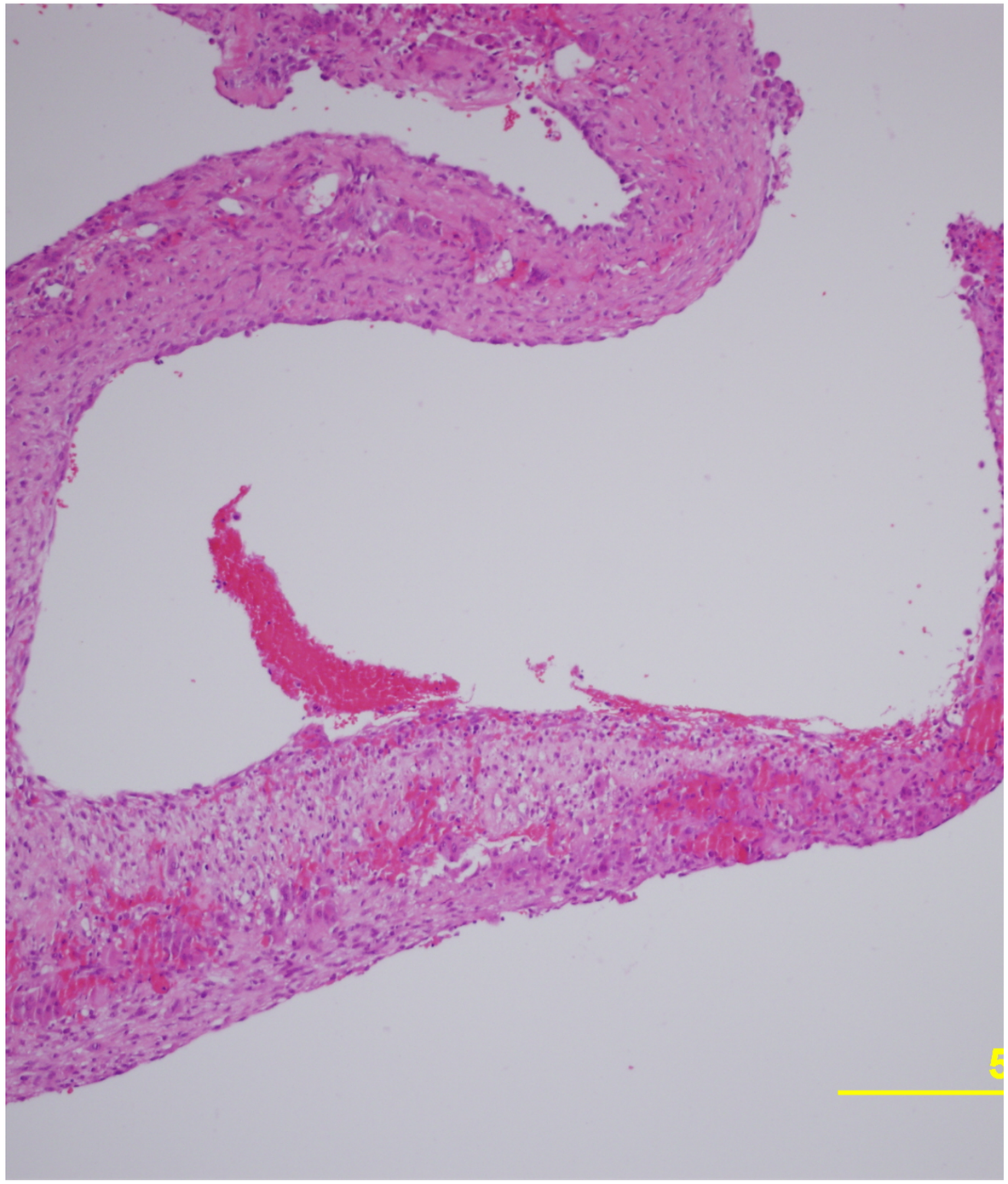

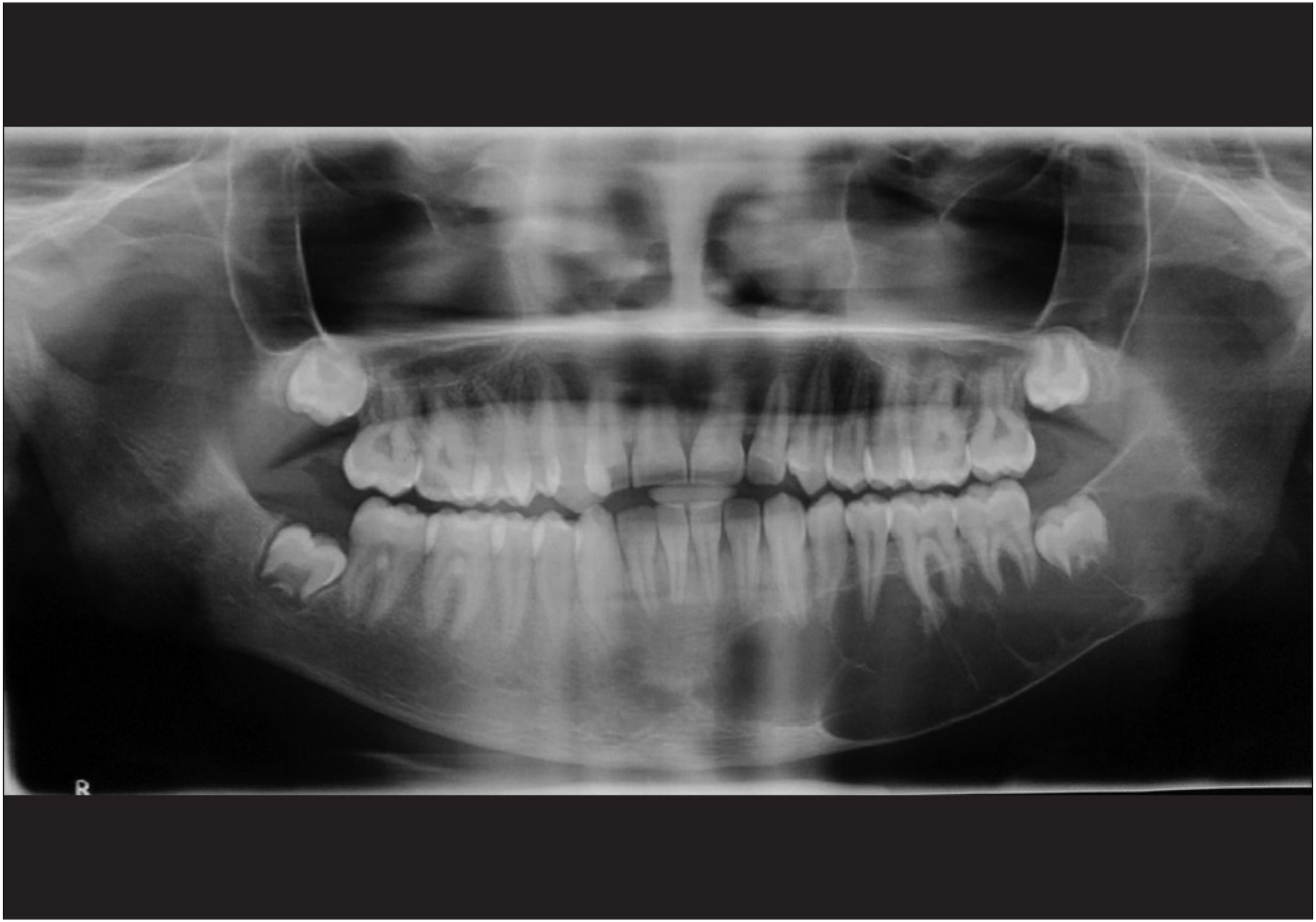
R

Hemanjiyoma

- En sık mandibula, posterior
- f♀= 2 x f♂
- Ekspansiyon, deformite, kanama
- Değişken litik lezyon
- Kavernöz ya da kapiller

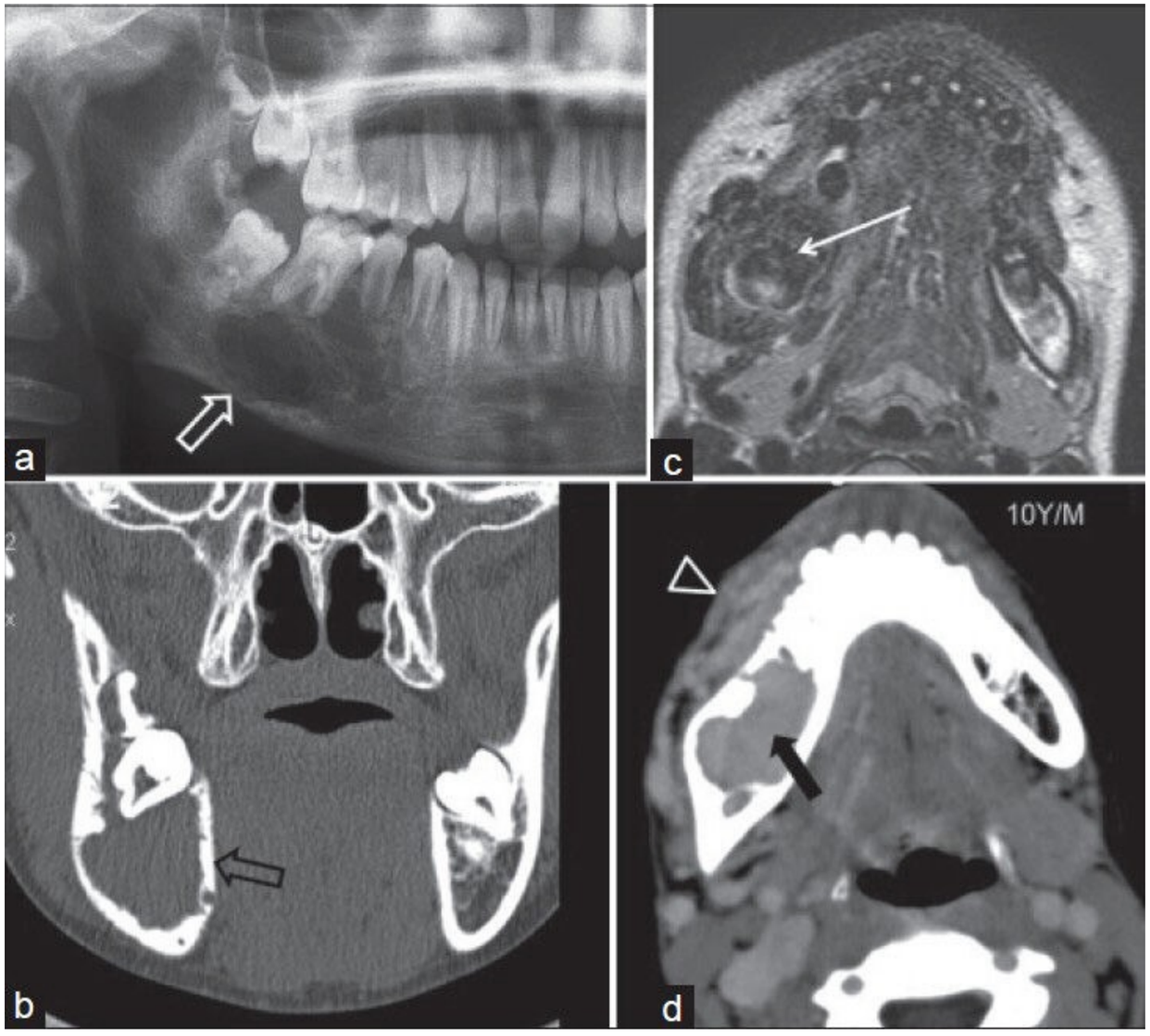

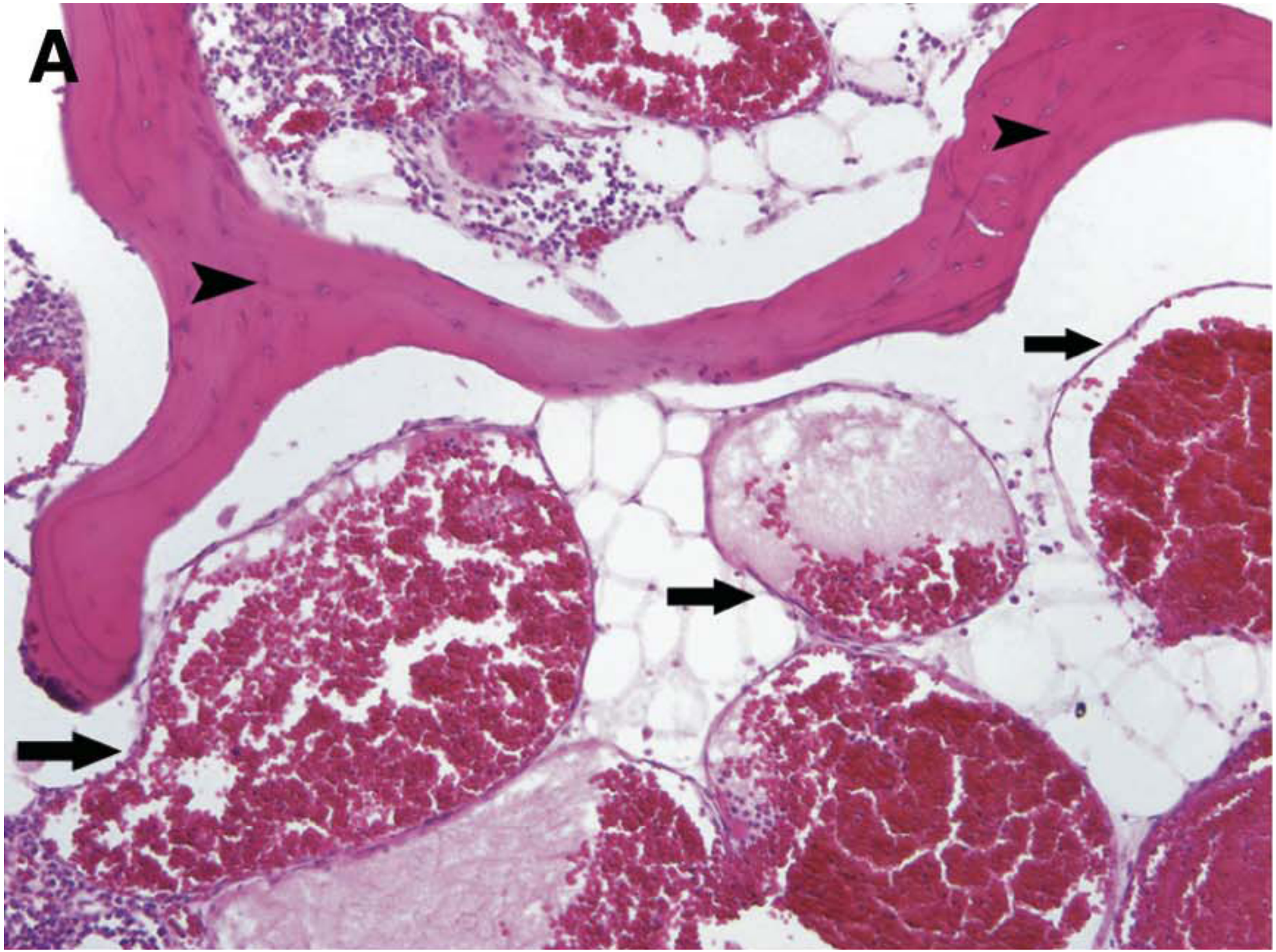
A

Langerhans hücreli histiyositoz

- Çocuklar ve genç erişkinler
- Lokalize, mültifokal, dissemine
- Her kemik olabilir
- f♂> f♀
- Ateş, ağrı, şişlik
- Değişken litik lezyon
- Bol eozinofil, tipik histiosit benzeri hücreler, mültinükleer dev hücreler

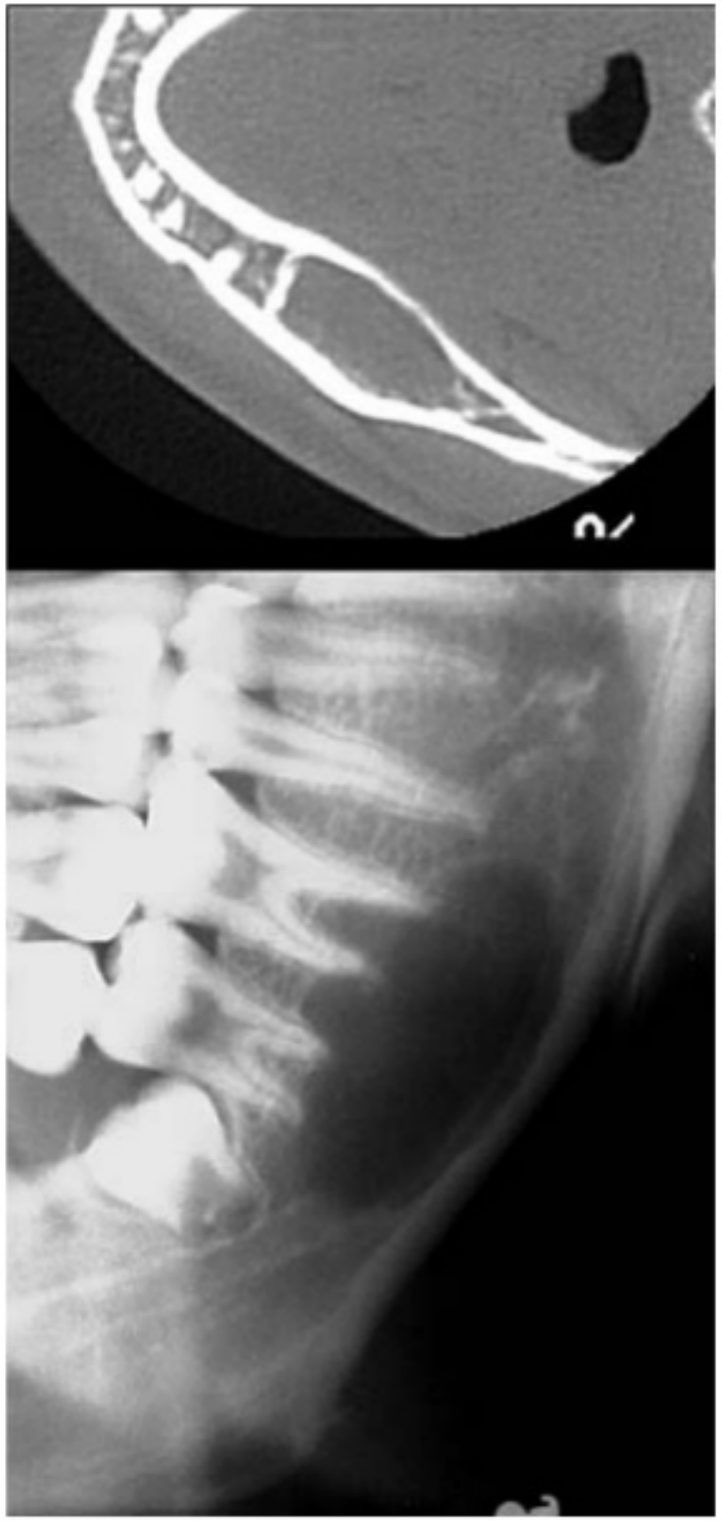

Langerhans hücreli histiyositoz

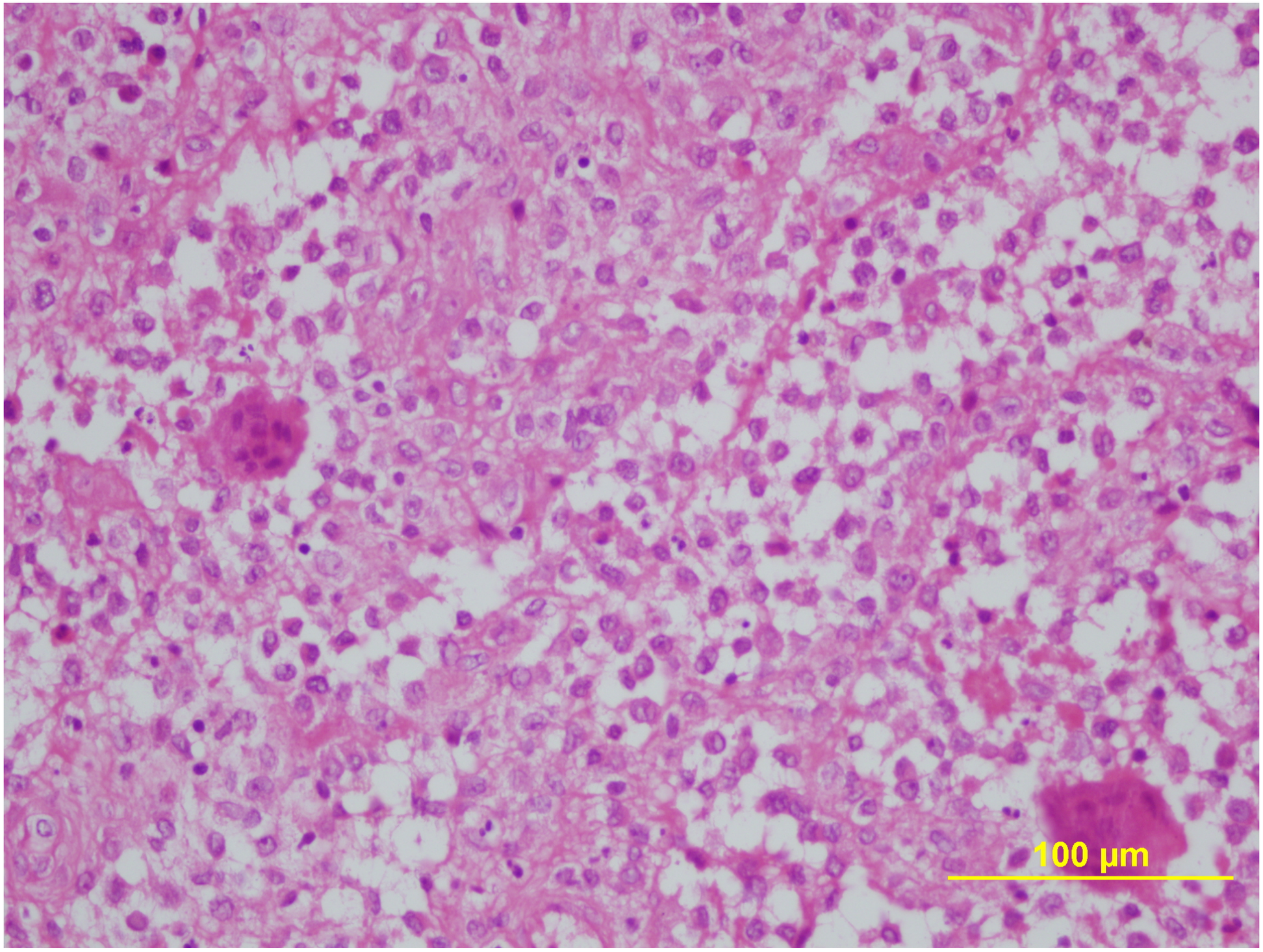

Osteoma

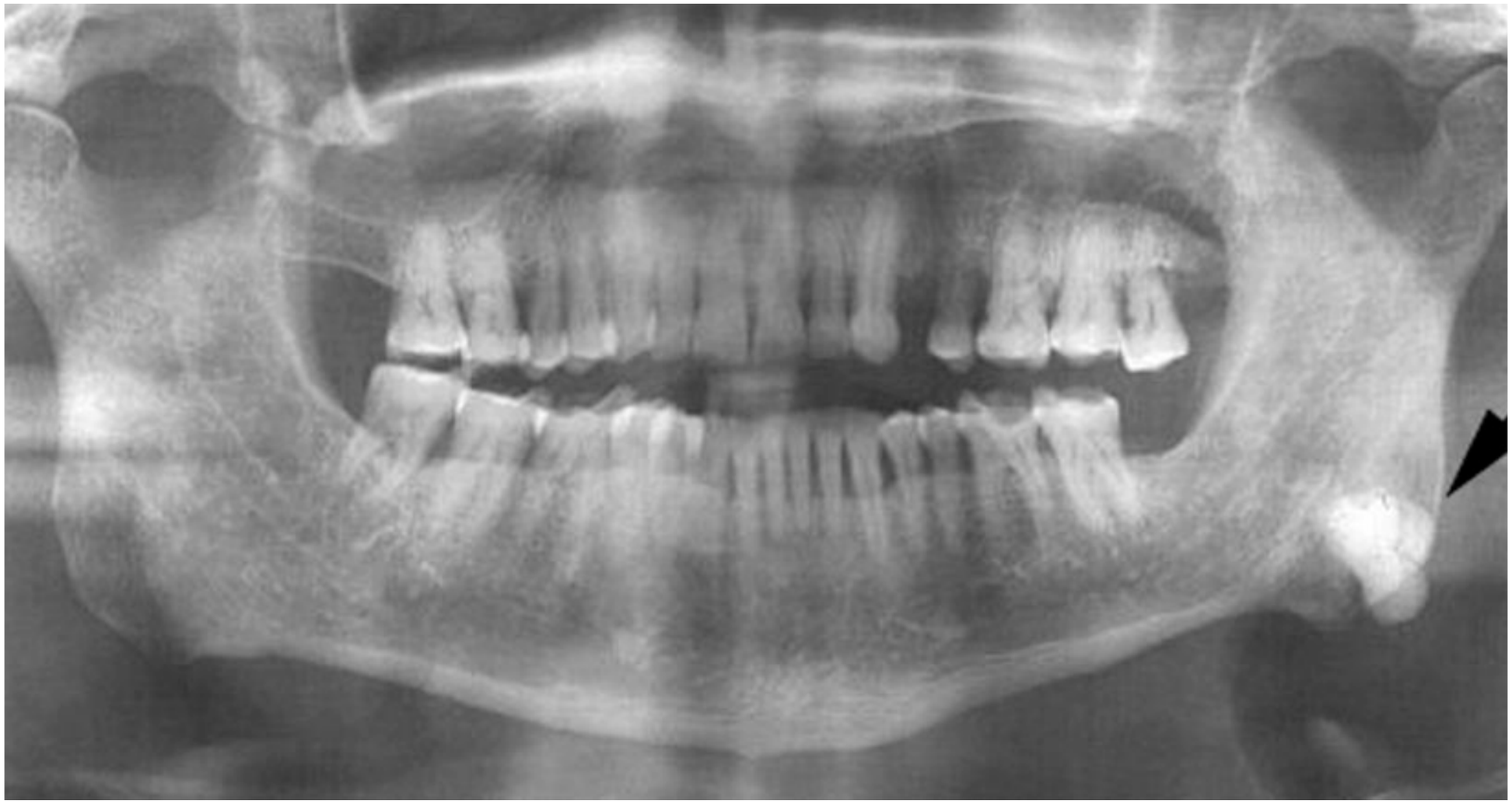

- 2-5. dekadlar
- f ♂= 2 x f ♀
- Her kemikte olabilir, sinüs içleri
- Kompakt sklerotik kemik dansitesi
- Matür /genç kemik olabilir
- Kortikal, trabeküler, karışık olabilir

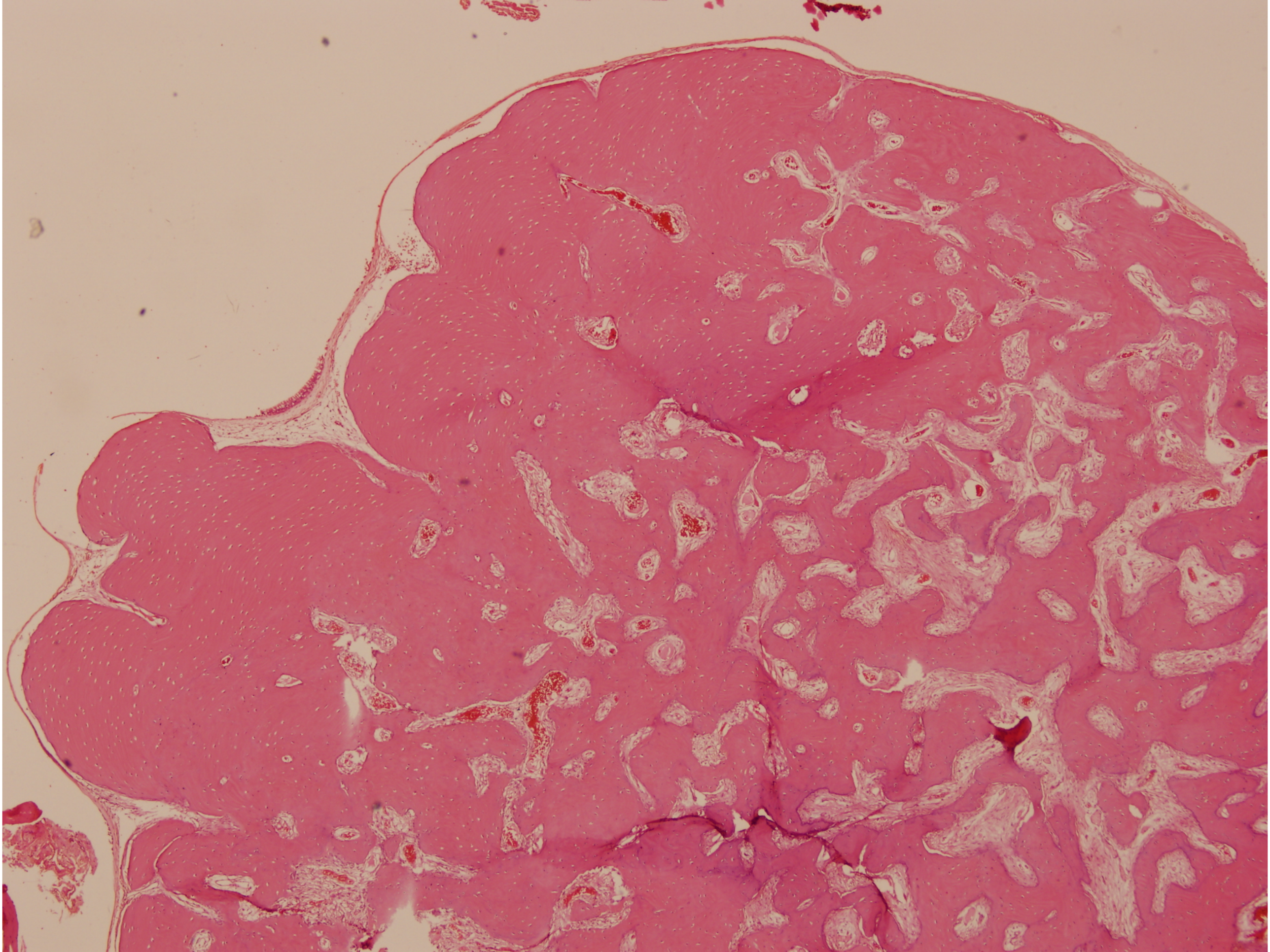

Kondroma

- Nadir, erişkinler <50
- En sık nazal septum ve etmoid sinüs, maksilla ve mandibulada olabilir
- Matür hiyalen kıkırdak lobülleri
- Kondrosarkomdan ayırt edilmesi güç
- Güvenli cerrahi sınır gerekli

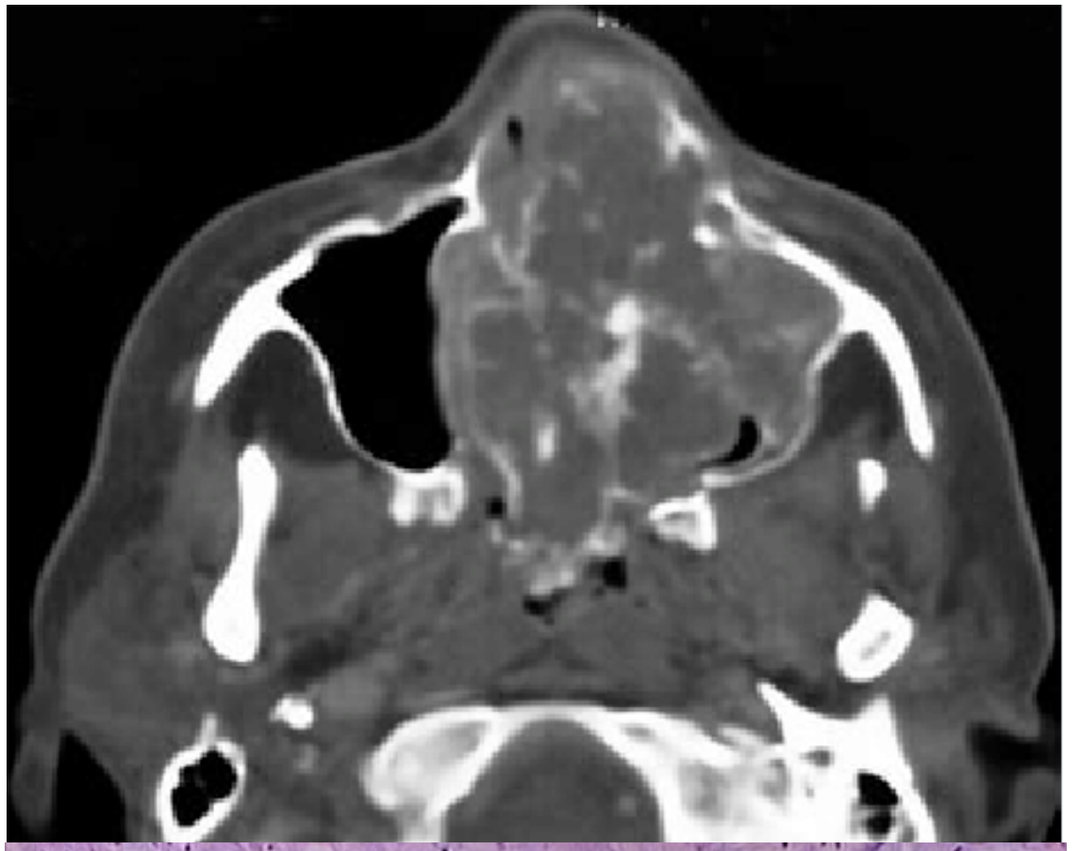

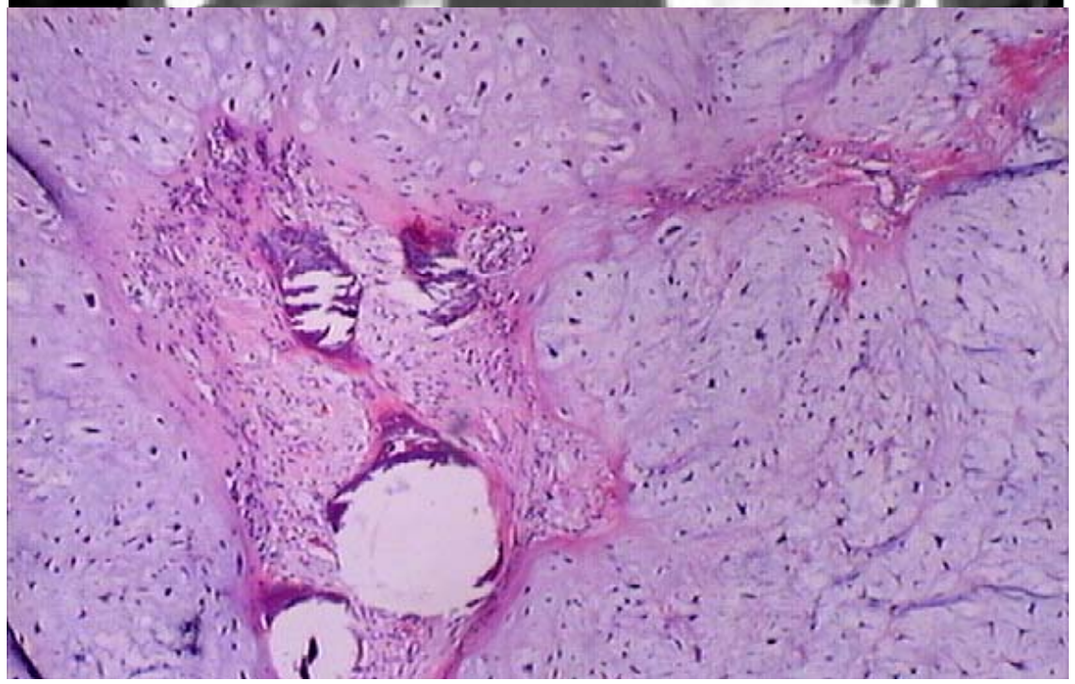

Torus ve ekzostoz

- Kemik yüzeyinden nodüler çıkıntılar
- Kalıtsal, ABD'de %16-25
- ***Torus palatinus, torus mandibularis***
- f♂> f♀
- **Ekzostoz:** Alveoler kemiğin bukkal kısmında çıkıntı
- Matür kortikal ve trabeküler kemik

Osteosarkom

- Tüm osteosarkomların %5'i çenede
- Paget, osteomiyelit, fibröz displazi, dev hücreli tümör, kemik infarktı zemininde oluşabilir
- f♂> f♀
- Çenede ortalama yaş 34
- f maksilla = f mandibüla
- Mandibulada en sık cisim, maksillada damak nadir
- Yüzey osteosarkomları: parosteal ve periosteal osteosarkom, nadir
- Osteoid matriks yapan malign mezenkimal tümör
- Ayrıca kondroblastik, fibroblastik, anevrizmal ya da küçük hücreli olabilir
- Çenede genelde kondroblastik ve yavaş seyirli

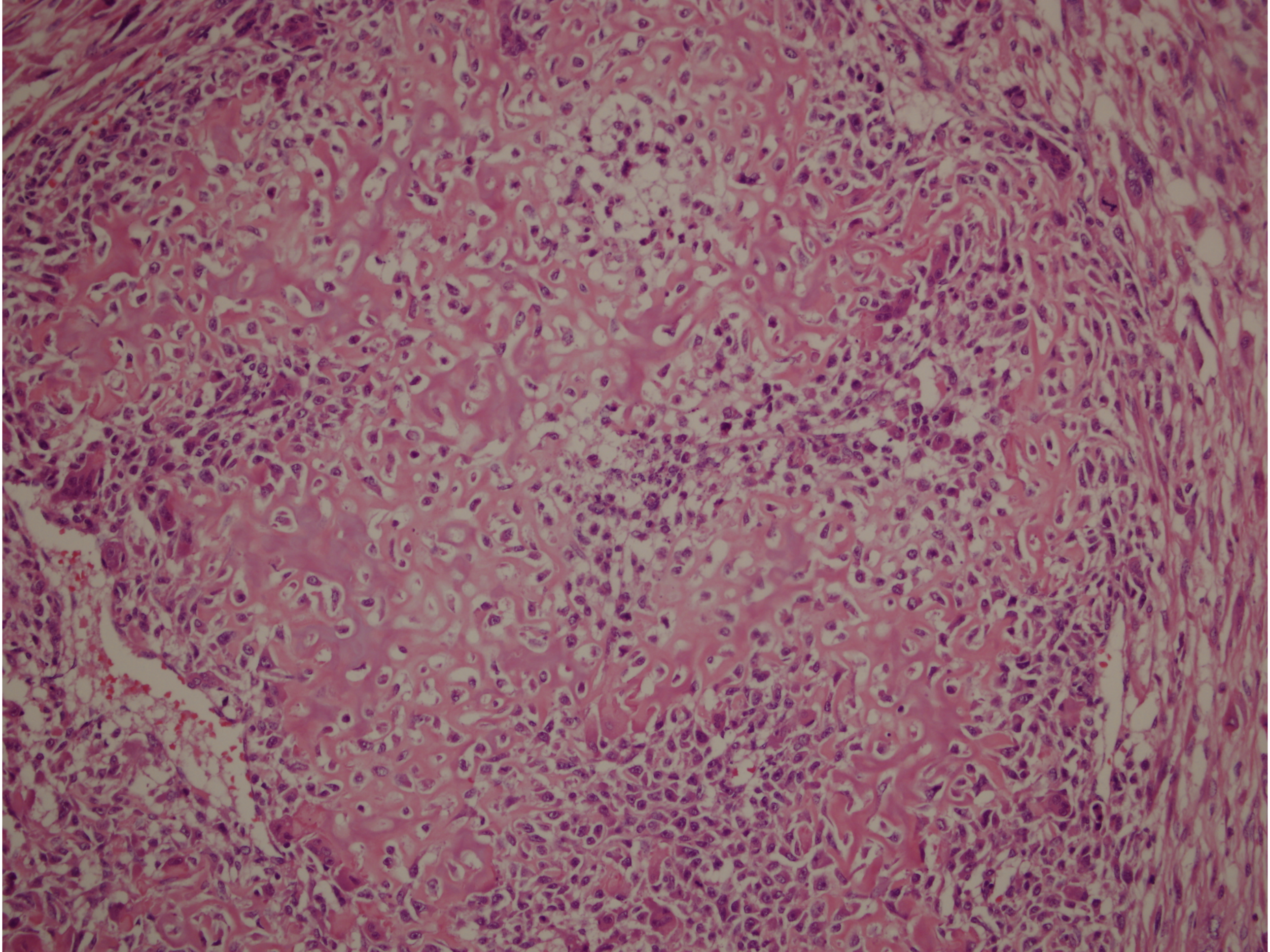

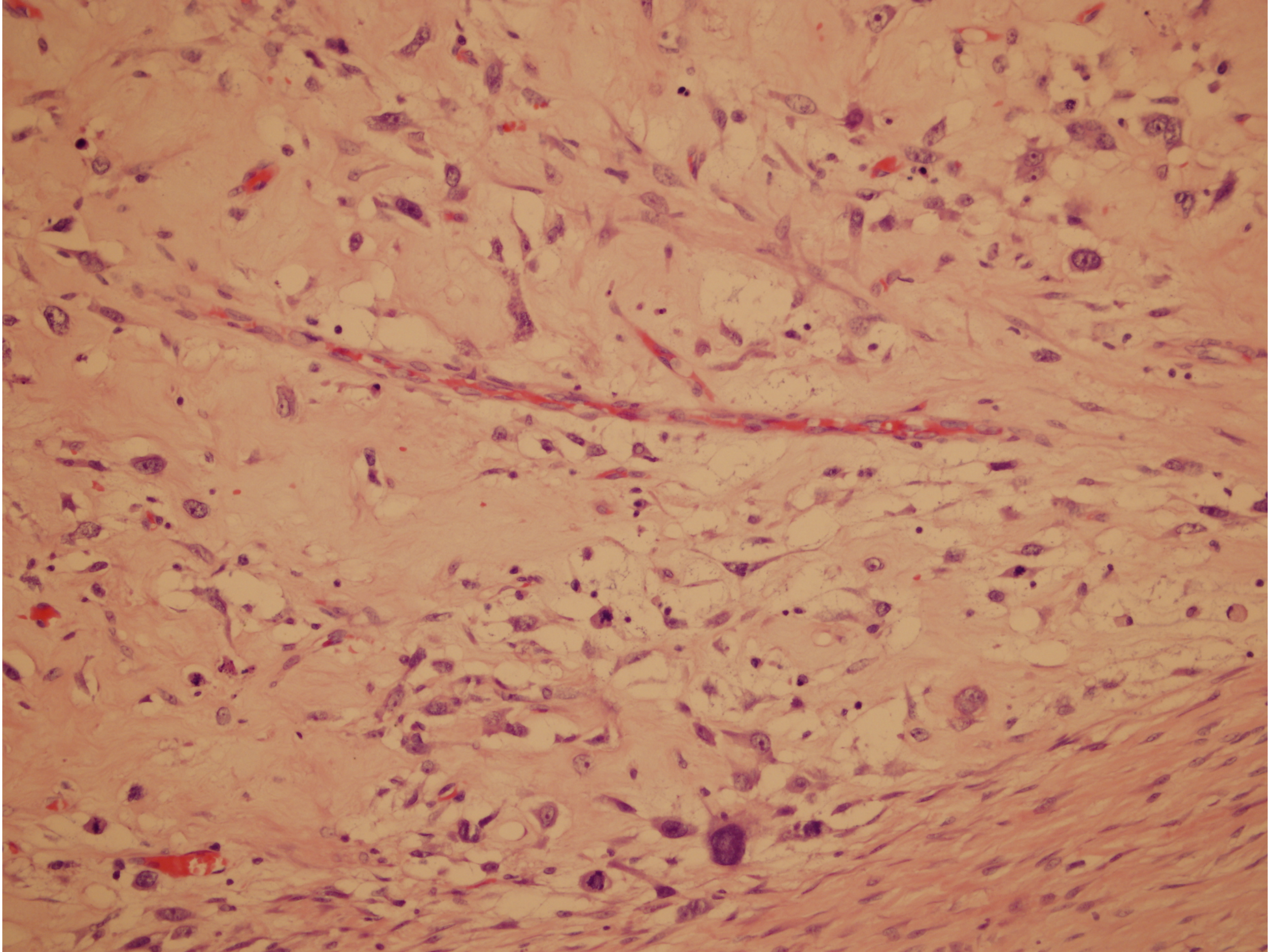

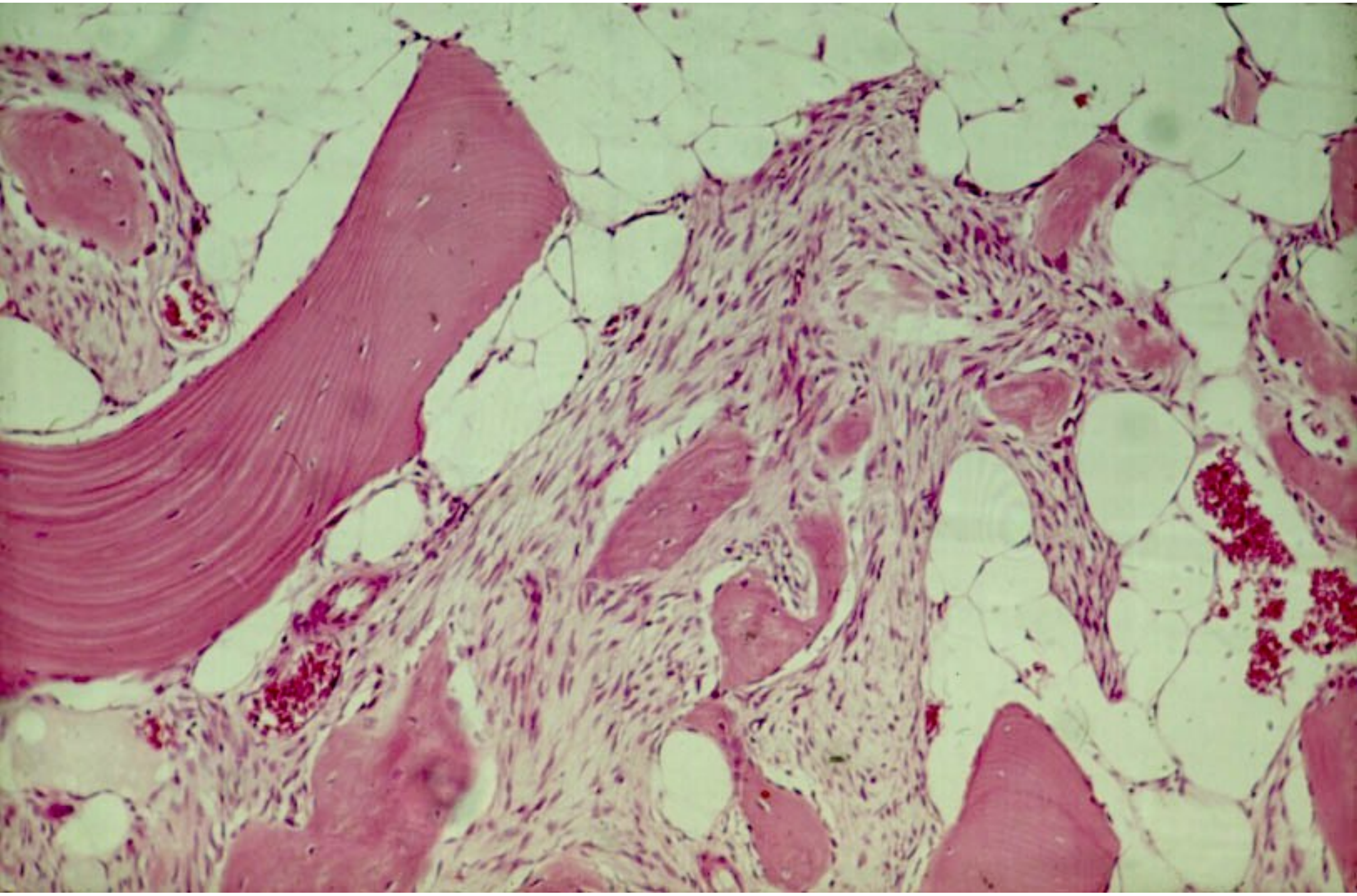

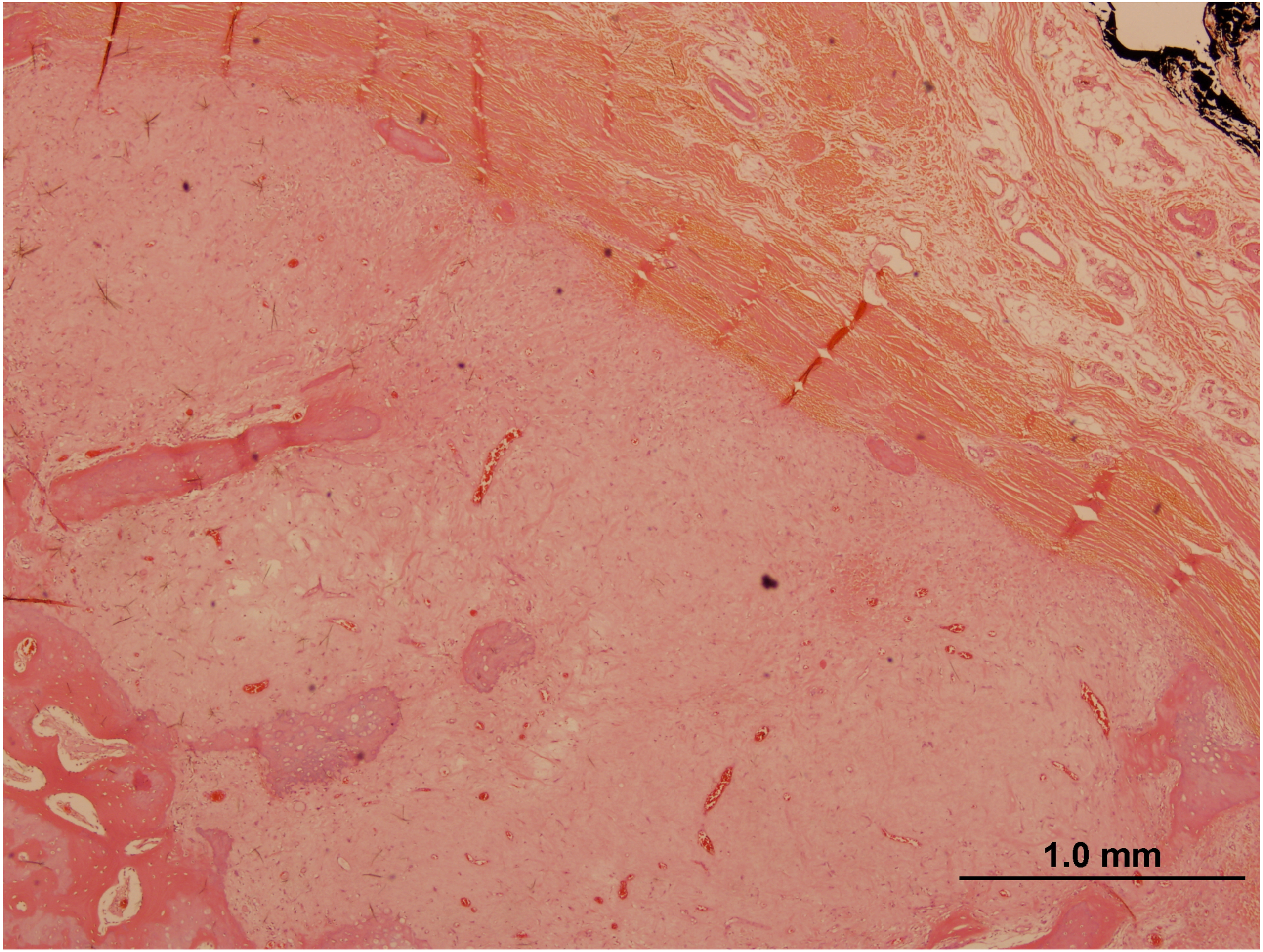
1.0 mm

Kondrosarkom

- Çenede çok nadir
- Daha çok maksillofasiyal bölgede, anterior ve damak bölgesi
- Erişkin ve ileri yaşlarda
- Derecesine göre sellülaritesi artan kıkırdak
- Derece I normal kıkırdak - kondrom gibi
- Tuzaklanmış kemik ve sinsi infiltrasyon

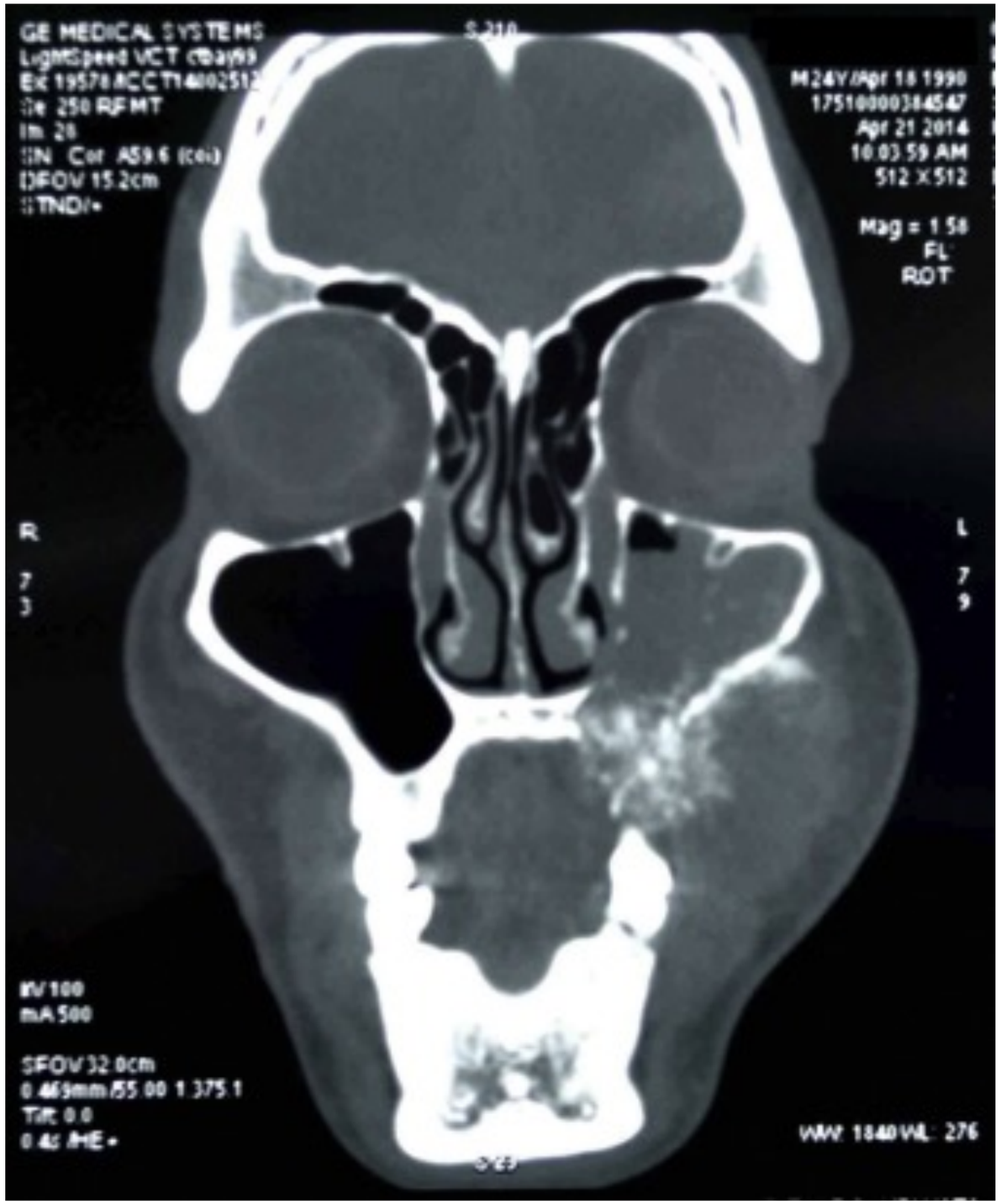

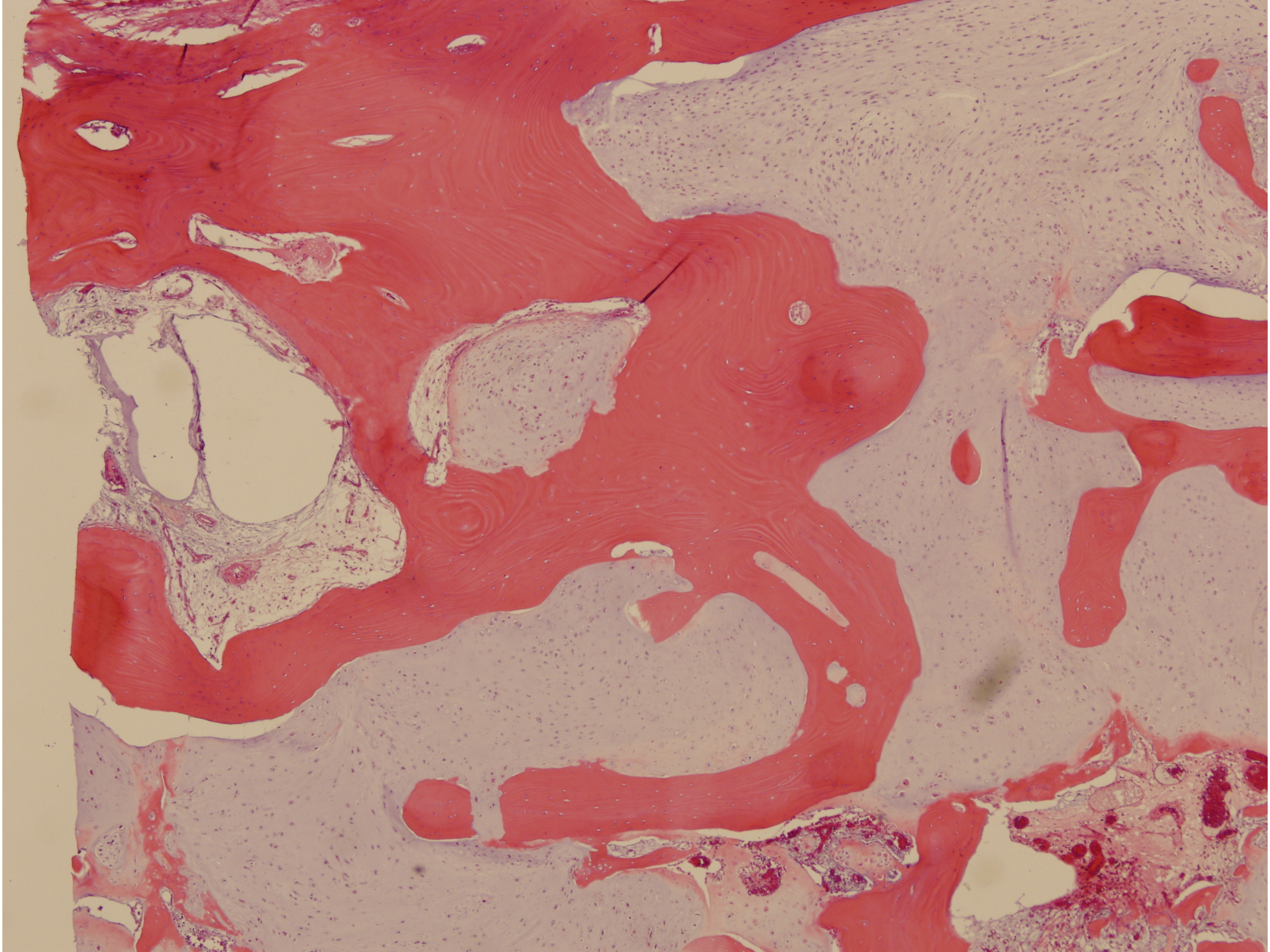

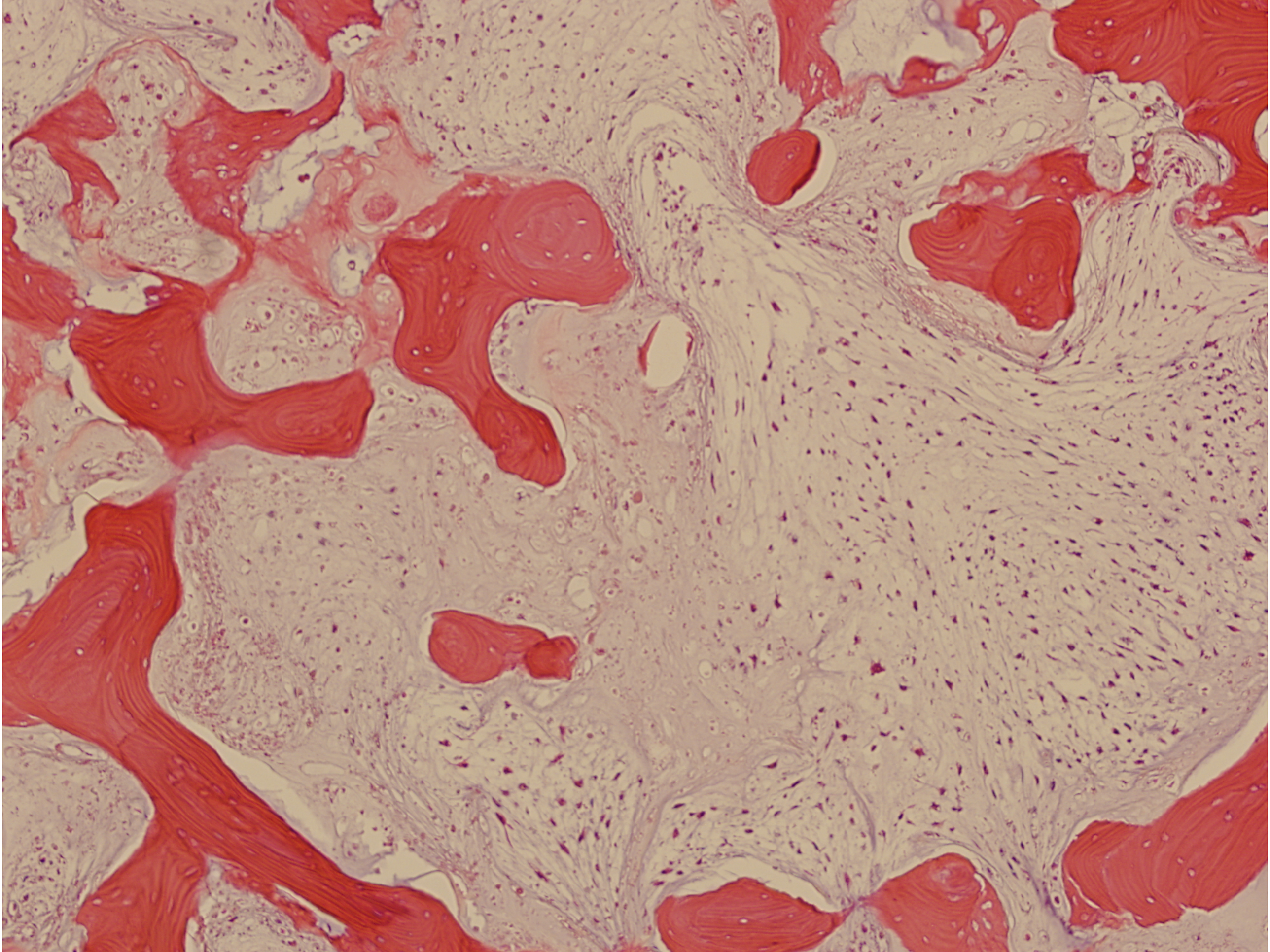

Ewing sarkomu

- Çocuk ve genç erişkin
- Uzun ve yassı kemikler
- Çenede en sık mandibuler ramus
- Çok agressif, büyük yumuşak doku kitlesi
- Başka kemiklere metastaz yapabilir
- Radyoloji osteomiyelitle karışabilir
- Üniform yuvarlak hücreler

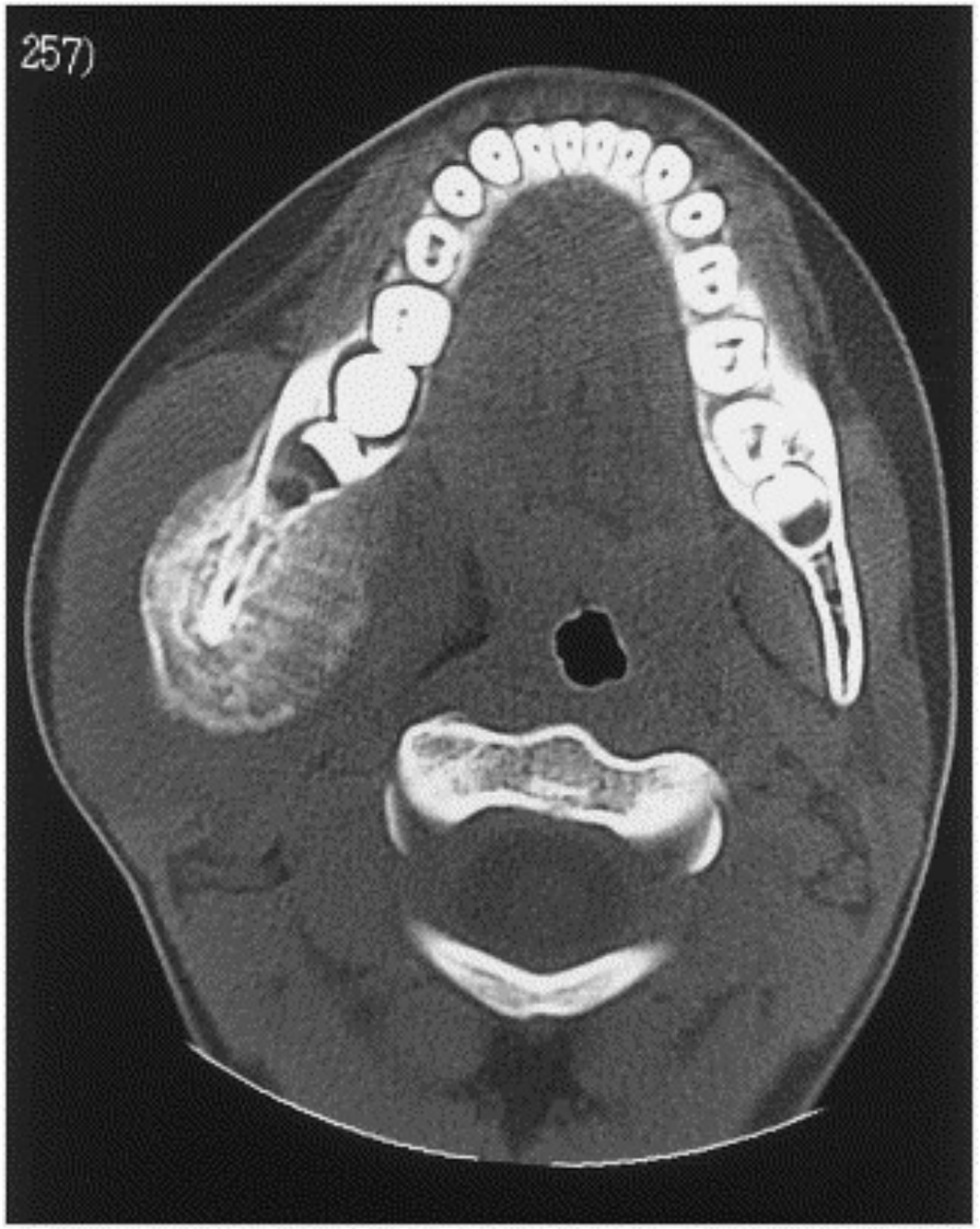

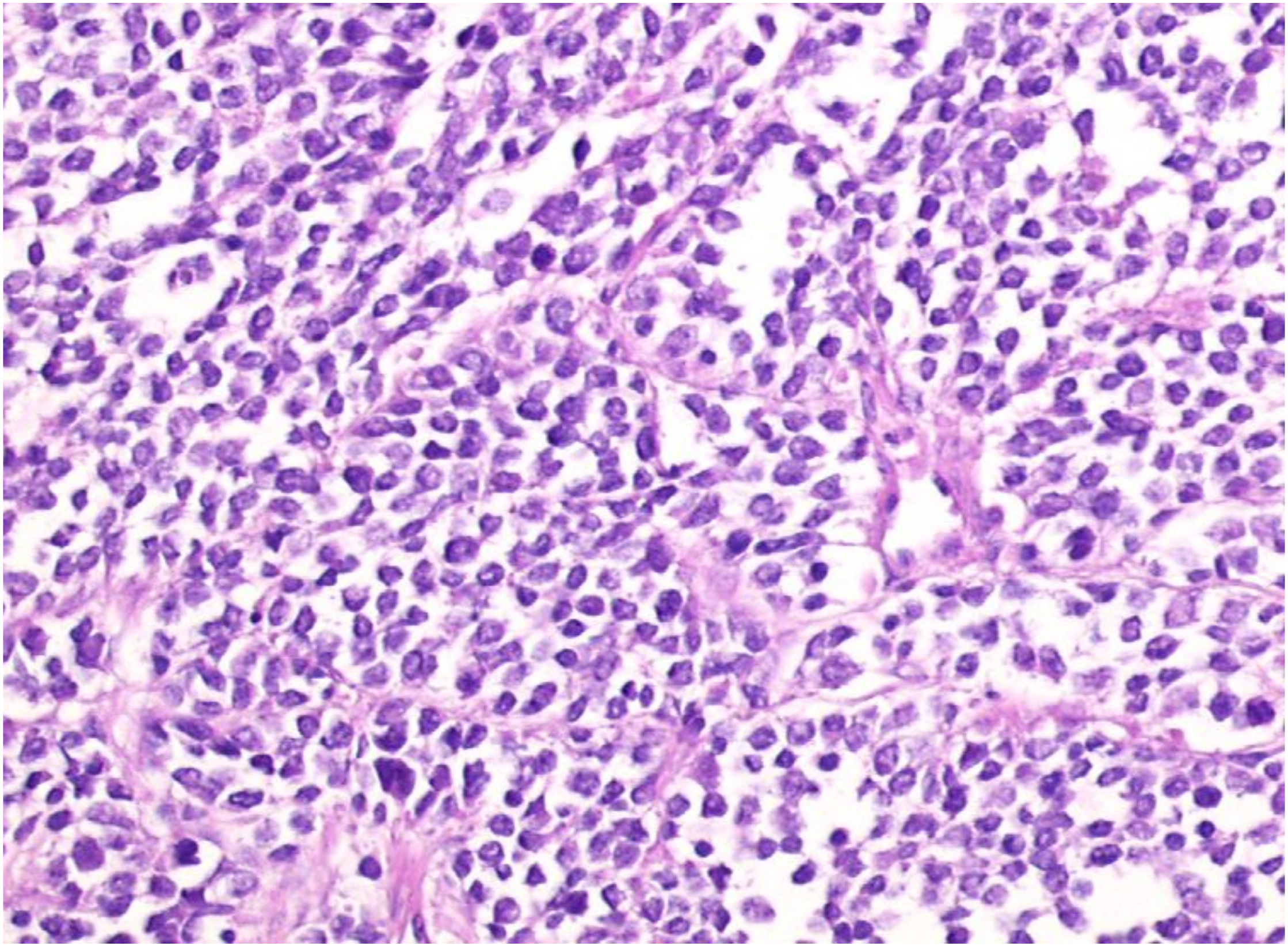

Burkitt lenfoması

- Çocuklar
- Baş-boyun lenfoid doku
- Çene kemiği tutulumu özellikle küçük çocuklarda (<3y)
- Malign B-lenfosit neoplazisi
- Çok agresif, hızla büyüyerek hava yolu - dolaşım problemi yaratabilir

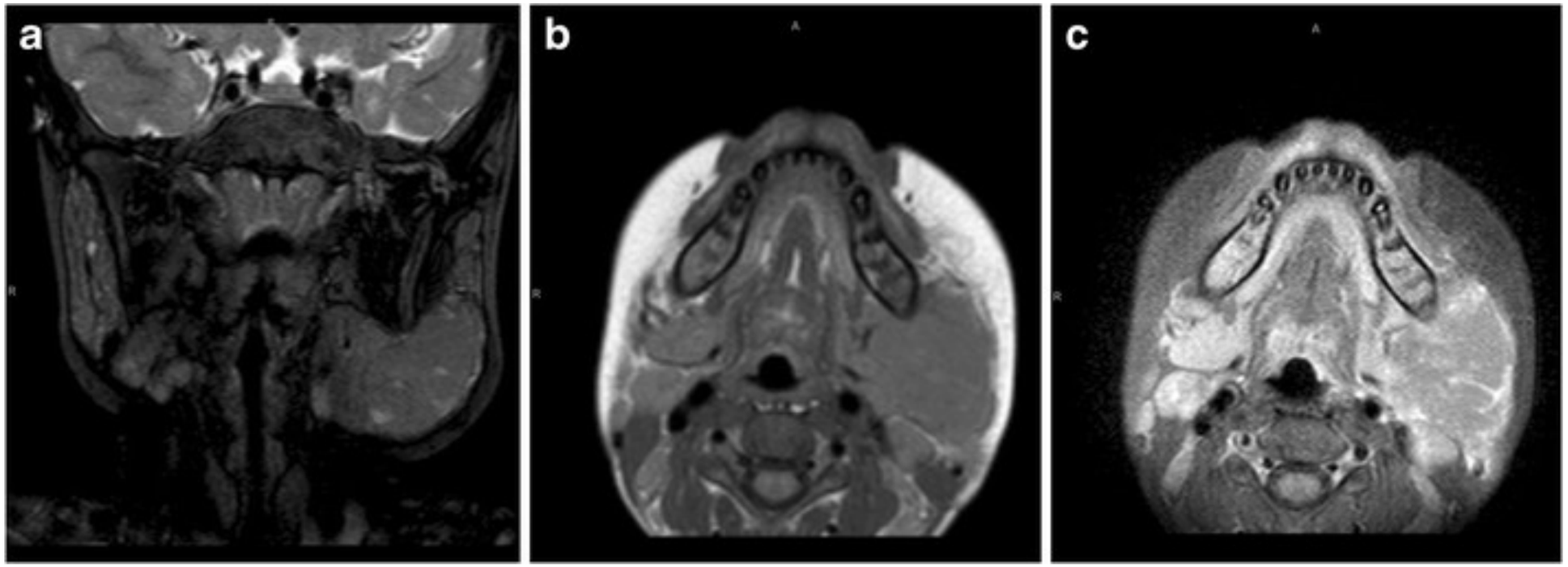

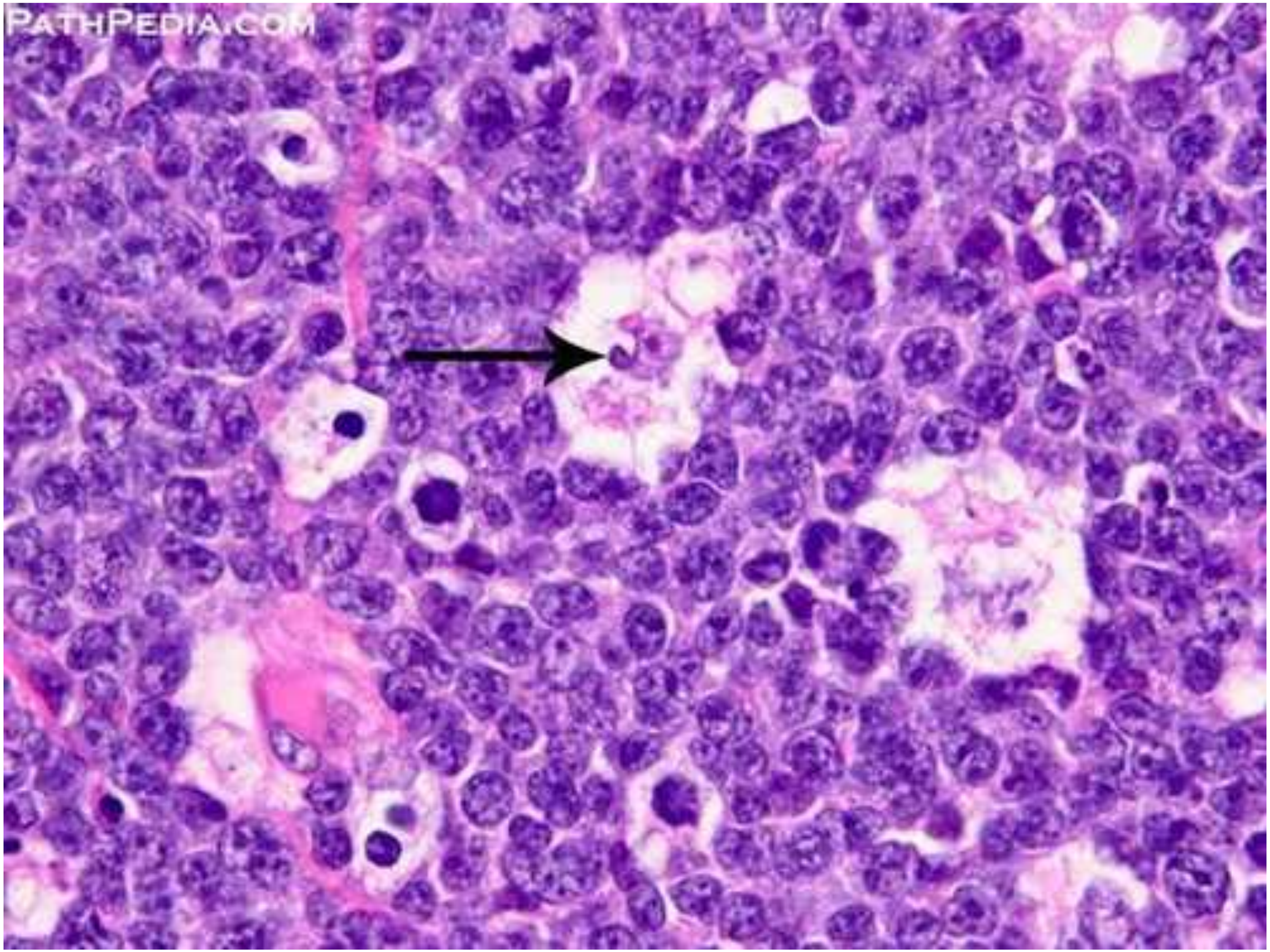
PATHPEDIA.COM

Plazma hücreli neoplaziler

- Plazmositom, mültipl miyelom
- 5. dekad sonrası, ortalama yaş 63
- Ağrı, diş problemleri, nadiren kitle farkedilir, %10 amiloidoz
- Zımba deliği gibi litik lezyonlar
- Matür plazma hücreleri, monoklonal

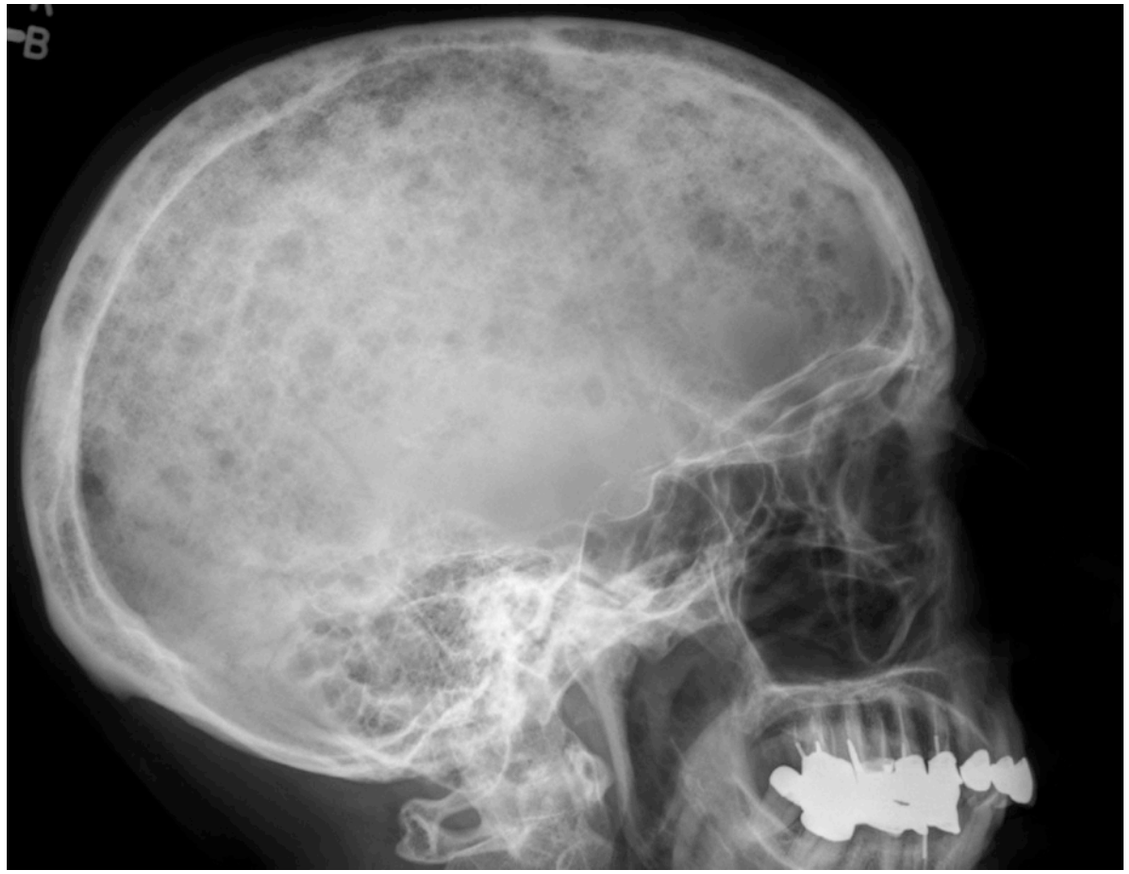

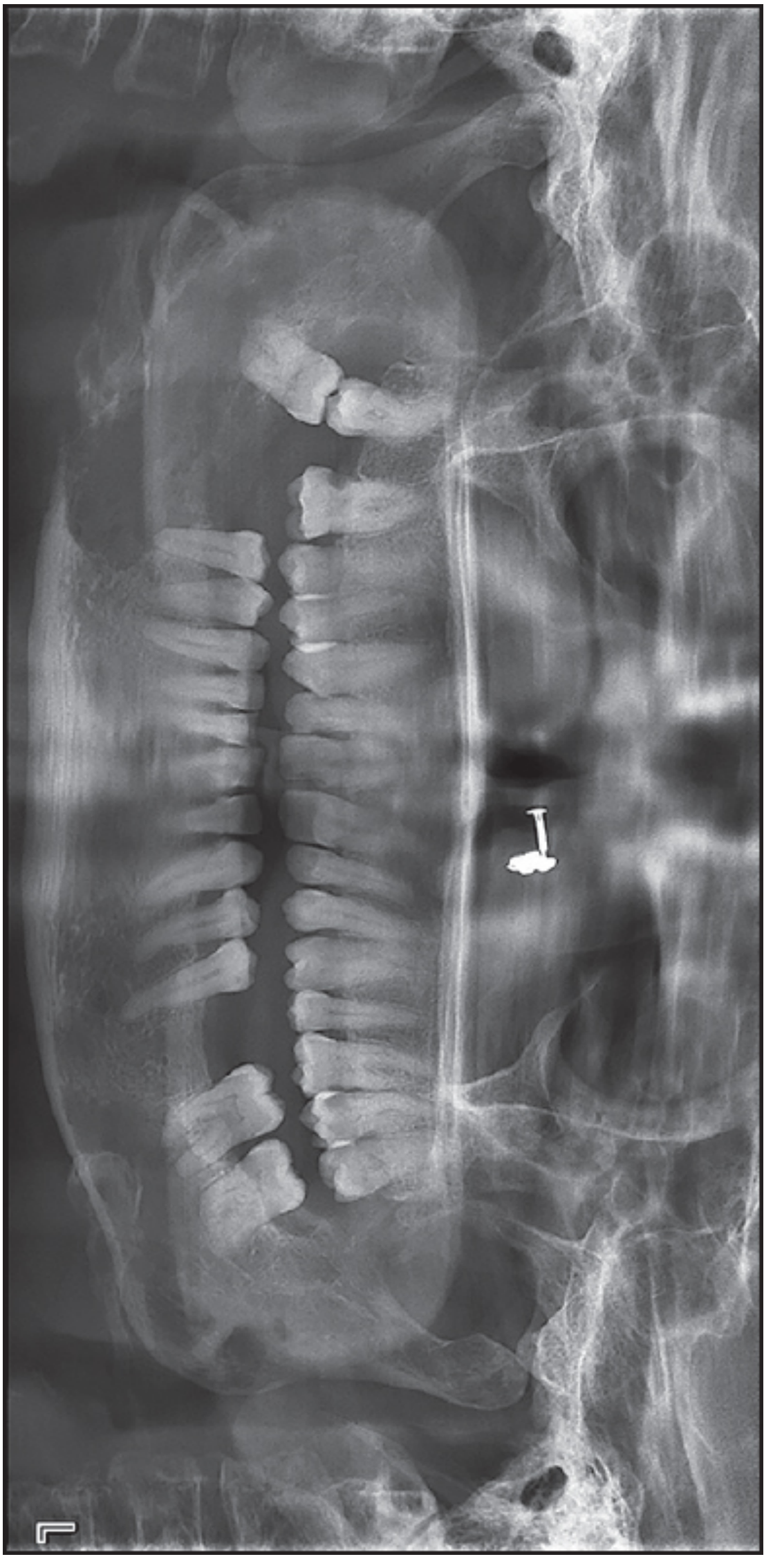

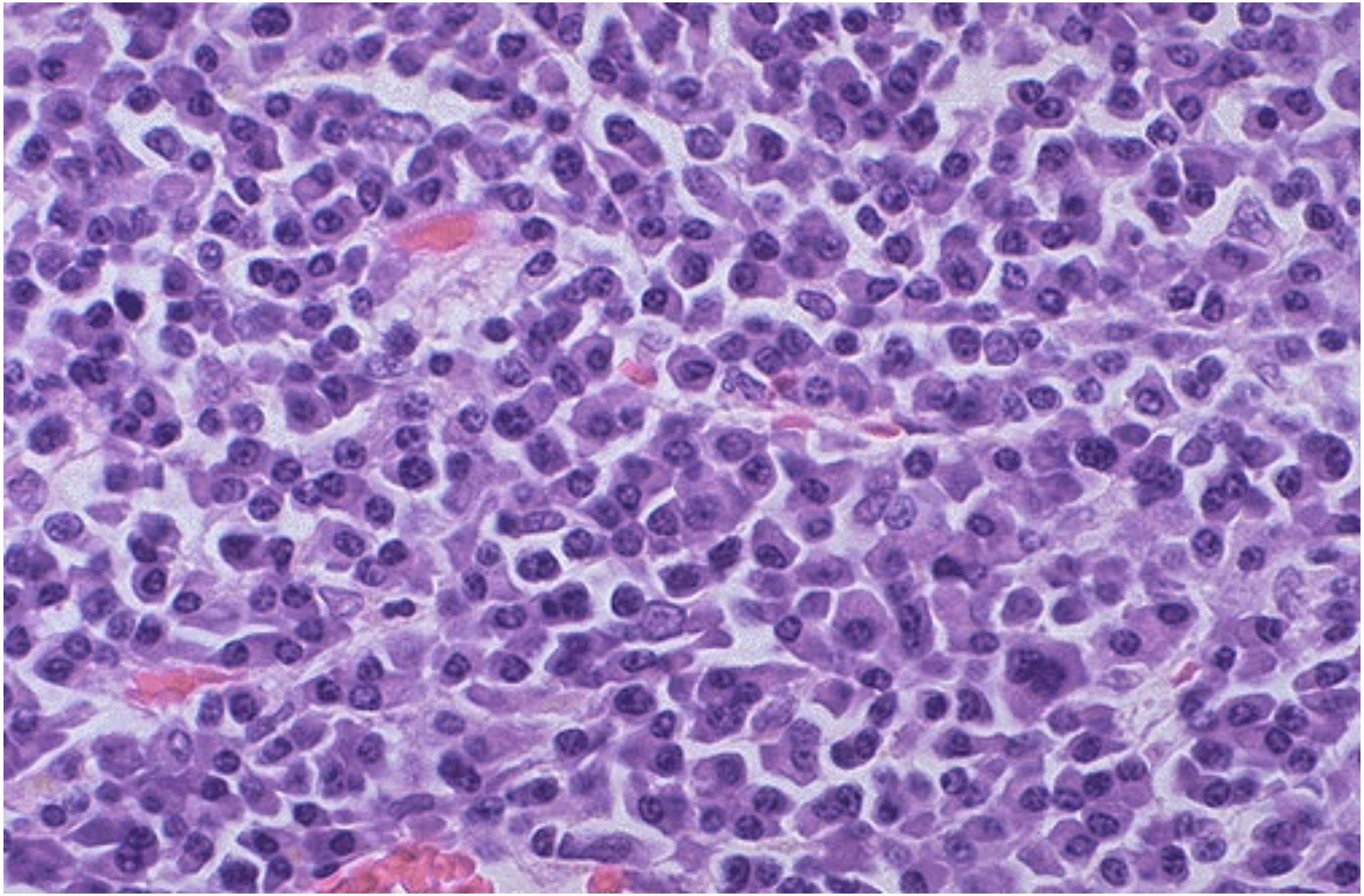

Immunohistochemistry in MM

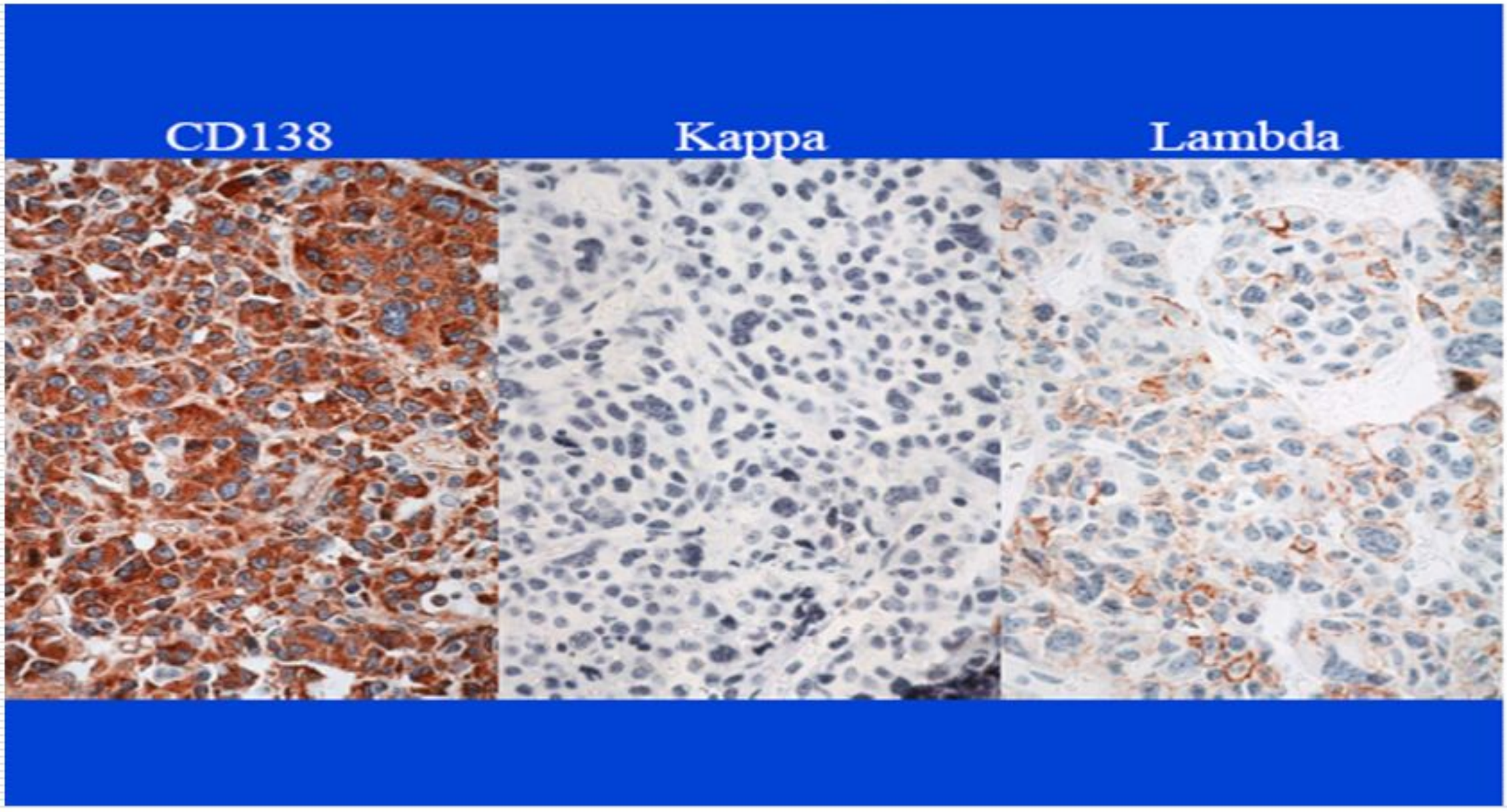

Metastatik tümörler

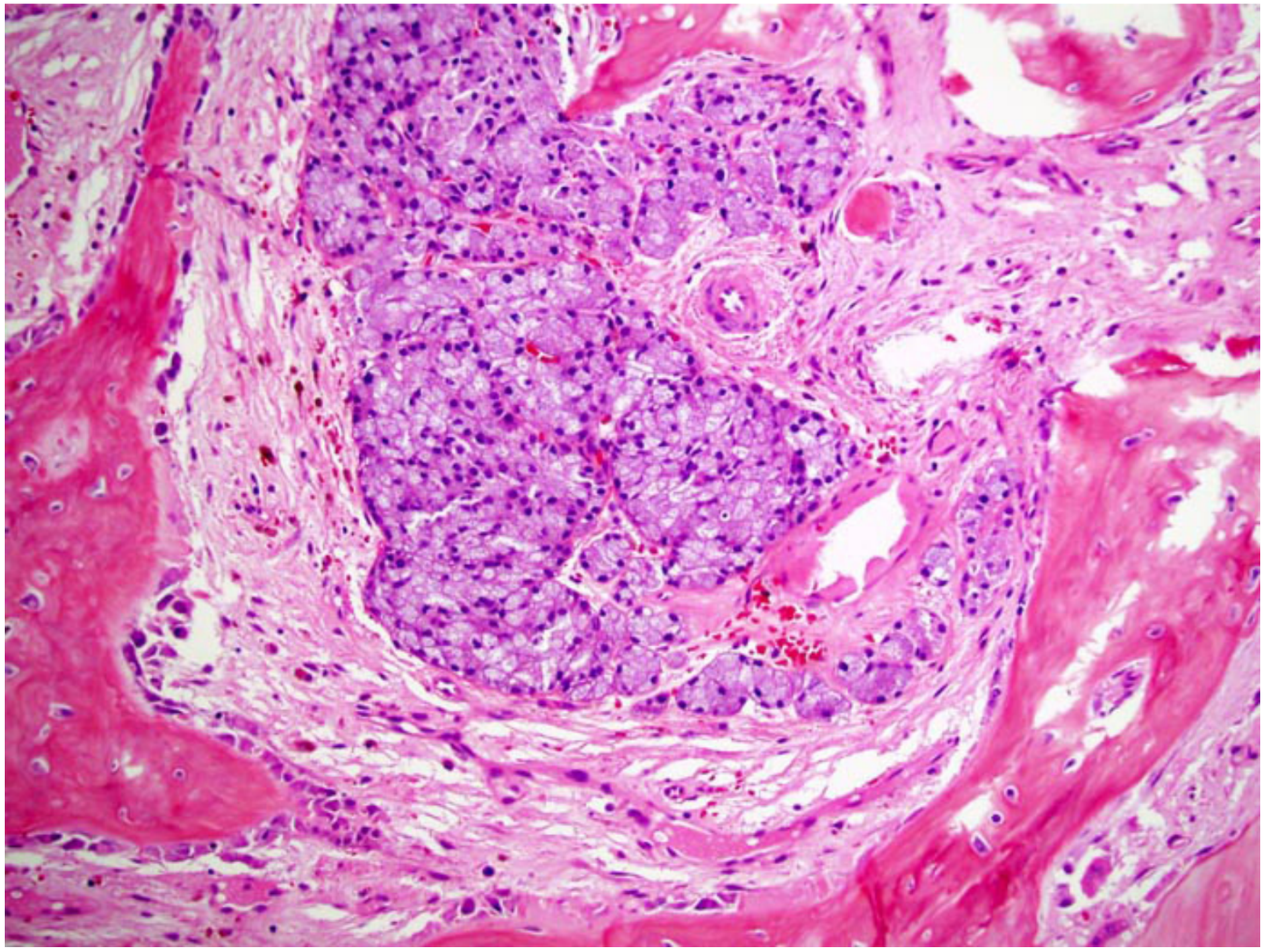

Epitelyal tümörler

Maksilla ve mandibülaya metastaz nadir

En sık meme, böbrek, akciğer, kolon, prostat ve tiroid kanserleri

Metastatik tümörler